

Expansive Growth of Atherosclerotic Plaques Assessed by VH-IVUS Association with TNF- α and OX-LDL Levels in Circulation

C. Ramos¹, P. Napoleão², C. Fondinho³, M. Selas³, M. Mota Carmo^{3,4}, R. Cruz Ferreira^{3,4}
and T. Pinheiro¹

¹IST/ITN, Instituto Superior Técnico, Universidade Técnica de Lisboa, E.N. 10, Sacavém, Portugal

²Instituto de Medicina Molecular, Av. Prof. Gama Pinto, Lisboa, Portugal

³Serviço de Cardiologia, Hospital de Santa Marta CHLC, Lisboa, Portugal

⁴CEDOC, Faculdade de Ciências Médicas, Universidade Nova de Lisboa, Campo Santana, Lisboa, Portugal

Keywords: VH-IVUS, Biomarkers, Expansive Plaque, Plaque Vulnerability.

Abstract: The identification of a vulnerable plaque through the quantification of soluble biomarkers would improve the diagnosis and treatment of coronary artery disease. Inflammation and LDL oxidative modification have been implicated in CAD. Disease severity and plaque vulnerability have recently been associated to expansive plaque growth, rather than constrictive growth which results in vessel stenosis. Forty CAD patients were admitted prospectively. VH-IVUS was performed and TNF- α and ox-LDL were quantified in the serum and plasma, respectively. Expansive plaques characterized by large EEL diameters and preserved luminal measures were associated to STEMI patients. Larger EEL diameter (≥ 4.6 mm²) was significantly associated to increases of TNF- α concentrations whereas larger plaque areas (≥ 13.0 mm²) associated with ox-LDL increases in the circulation. Hence, TNF- α and ox-LDL may be indicators of plaque vulnerability.

1 INTRODUCTION

Coronary artery disease (CAD) has been studied for decades but many of the mechanisms underlying both the establishment and the development of this disease are yet to be understood. (Fayard and Fuster, 2001); (Choi et al., 2008); (Greco et al., 2010) It is generally accepted that oxidized low density lipoproteins (ox-LDL) and tumour necrosis factor - α (TNF- α) are involved in CAD. Oxidative modification of LDL plays a part in the formation of the fatty streak which constitutes the first step in atheroma formation. During the progress of atherosclerosis the inflammatory process is highly activated, involving many types of cells and cytokines, namely TNF- α . (Goldstein and Ross, 1987); (Hansson, 2005)

The identification of vulnerable coronary atherosclerotic plaque is one of the ultimate goals of coronary imaging. There is increasing evidence suggesting the most vulnerable plaques are not associated with constrictive growth which causes vessel stenosis, but with outwards, expansive growth – positive remodelling. (Hong et al., 2012) IVUS is

a widespread modality used for the direct visualization of coronary lumen, vessel wall, and atherosclerotic plaque. It allows the measurement of plaque area and any thickening of arterial walls (Amato et al., 2007); (Böse et al., 2007), which is an important advantage over coronary angiography, the golden standard method of coronary disease assessment. In addition to lumen diameter, IVUS provides plaque measures and histological structure by analysing the radiofrequency spectra.

Noninvasive identification of rupture-prone plaques would dramatically improve risk stratification of both symptomatic and asymptomatic patients. Therefore, associations between the expansive growth of the atherosclerotic plaque and soluble bioindicators may provide important information that enhances the precision of clinical and laboratory variables used to assess patients at risk of CAD or of plaque rupture (Ramos et al., 2013); (Hong et al., 2012).

2 OBJECTIVES

The aim of this study was to explore the possible association of the atherosclerotic plaque characteristics, assessed by VH-IVUS, and both the inflammatory response and LDL oxidative modification, evaluated systemically. In particular, we investigated measurements for the plaque expansive growth and the soluble markers TNF- α and ox-LDL.

3 METHODS

Forty patients were enrolled in this prospective study at the Cardiology Service of Santa Marta Hospital (CHLC, Lisbon, Portugal). All patients underwent standard diagnostic procedures and were treated accordingly.

Peripheral blood was drawn from all patients into blood collection tubes (Vacuette) with appropriate anti-coagulant. Biochemical analyses were routinely performed in the hospital, including the measurement of troponin T, N-terminal pro-brain natriuretic peptide (NT-proBNP) and C-reactive protein (CRP). Serum and plasma were also collected for ox-LDL and TNF- α determination by enzyme-linked immunosorbent assays (ELISA). Samples were stored at -80°C until analysis, for a period not exceeding 6 months. The concentration of ox-LDL was measured in plasma and TNF- α in serum using ELISA commercial kits (R&D Systems). Patients characterization is summarized in Table 1.

VH-IVUS was conducted in all patients and data was recorded. VH-IVUS acquisition was performed using an EagleEye catheter (20 MHz) at pullback speed of 0.5 mm/sec. For each lesion, vessel, lumen and atheroma measurements were obtained based on total number of cross-sections analysed throughout the region of interest. Lesion borders were established using the leading edges of external elastic lamina (EEL) and the luminal contour. The radiofrequency backscatter information was reconstructed using In-Vision gold commercial software (Volcano Corporation, USA). The percentages of fibrotic, fibro-fatty, calcified and necrotic core were assessed.

The relationship between plaque characteristics and biomarkers was evaluated by correlation. Plaque measurements were categorized according to median value (below or above) to assess biomarker dependence on plaque morphology and content changes. Differences between categories were

assessed using a Mann-Whitney test. The results were considered significant for $p < 0.05$.

Table 1: Patients clinical, demographic and biochemical characterization. Results are presented in median (Q25 – Q75), unless specified otherwise. STEMI – ST-elevation myocardial infarction; NSTEMI – non-ST-elevation myocardial infarction; SA – stable angina; UA – unstable angina; SI – silent ischemia; CRP – C-reactive protein; NT-proBNP – N-terminal pro-brain natriuretic peptide; ox-LDL – oxidized low density lipoprotein; TNF- α – tumour necrosis factor- α .

Clinical	STEMI	5, 13
	NSTEMI	7, 18
	SA	13, 33
	UA	11, 28
	SI	3, 8
Demographics	Male sex (n, %)	26, 67
	Age (y)	64 (57 – 71)
	Weight (kg)	74 (67 – 80)
	Height (m)	1.7 (1.6 – 1.7)
Risk factors / Co-morbidities	Smoking (n, %)	6, 16
	Obesity (%)	23, 62
	Hypercholesterolemia (n, %)	25, 76
	Arterial hypertension (n, %)	28, 72
Biochemical analysis	Diabetes mellitus (n, %)	17, 44
	CRP (mg/l)	4.3 (1.8 – 16.5)
	Troponin (ng/ml)	0.06 (0.01 – 0.15)
Soluble parameters	Pro-BNP (pg/ml)	203 (64 – 916)
	ox-LDL (U/l)	50.8 (38.4 – 66.2)
	TNF- α (pg/ml)	2.5 (0.9 – 5.8)

4 RESULTS

The plaques in coronary segments of interest were evaluated for morphological characteristics. The minimum, maximum and median values of plaque and lumen dimensions were determined. Plaque composition was assessed in sections of the major stenosis region.

The plaque characteristics measured are summarized in Table 2.

Plaque morphology measurements were determined in all patients and results were compared among the different groups. STEMI patients showed larger plaques than:

a) NSTEMI patients (100% STEMI patients with EEL diameter ≥ 4.6 mm against 29% NSTEMI patients, $p=0.028$; 100% STEMI patients with EEL area ≥ 17.0 mm² against 29% NSTEMI patients, $p=0.028$; 100% STEMI patients with plaque area ≥ 13.0 mm² against 15% NSTEMI patients, $p=0.047$);

b) SA patients (100% STEMI patients with EEL diameter ≥ 4.6 mm against 46% SA patients, $p=0.041$; 100% STEMI patients with EEL area ≥ 17.0 mm² against 46% SA patients, $p=0.041$; 100% STEMI patients with plaque area ≥ 13.0 mm² against 38% NSTEMI patients, $p=0.022$);

c) UA patients (median EEL diameter of 4.9mm for STEMI patients and of 4.6mm for UA patients, $p=0.005$; median EEL area of 19.6mm² for STEMI patients and of 16.6mm² for UA patients, $p=0.003$; median plaque area of 12.5mm² for STEMI patients and of 11.0mm² for UA patients, $p=0.027$).

Table 2: Atherosclerotic plaque measurements obtained by VH-IVUS. Results of the plaque morphology and composition are presented in median (Q25 – Q75).

Plaque characteristics		
Stenosis (%)		76.8 (65.6 – 83.7)
Fibrotic tissue (%)		58.4 (48.8 – 70.1)
Fibro-fatty tissue (%)		9.7 (6.7 – 20.7)
Calcified tissue (%)		11 (3.1 – 18.3)
Necrotic core (%)		15.8 (10.3 – 21.7)
Lumen	area (mm ²)	2.2 (1.9 – 2.7)
	diameter (mm)	3.6 (2.9 – 5.0)
External elastic lamina	diameter (mm)	4.6 (4.2 – 4.9)
	area (mm ²)	17.0 (14.3 – 19.3)
Plaque area (mm ²)		13.0 (10.0 – 15.0)
Plaque burden (%)		77.0 (66.3 – 83.6)

The atherosclerotic plaque physical characteristics obtained by VH-IVUS were studied and related with oxidative and inflammation bioindicators measured in the blood circulation, e.g. ox-LDL and TNF- α .

Figure 1 shows that the concentration of TNF- α significantly increased for large plaques, as expressed by EEL diameter (Figure 1) ($p=0.049$).

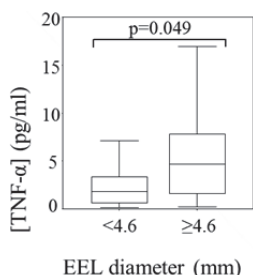


Figure 1: Box-plot representation of TNF- α concentration relative to EEL diameter <4.6 mm and ≥ 4.6 mm.

Figure 2 shows that the concentrations of ox-LDL were also significantly associated with the atheroma dimensions. Higher ox-LDL

concentrations are associated to large plaque areas, above median value (area ≥ 13 mm²) ($p=0.044$).

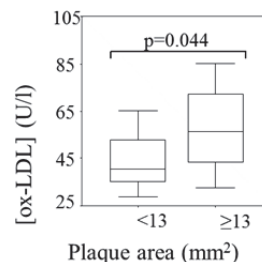


Figure 2: Box-plot representation of ox-LDL concentration relative to plaque area <13 mm² and ≥ 13 mm².

5 DISCUSSION

Atherosclerosis primarily affects the arterial wall and there is increasing evidence that supports the idea that positive remodelling, more than vessel stenosis, is associated to plaque vulnerability. (Hoffman et al., 2006); (Böse et al., 2007); (Napoleão et al., 2011); (Hong et al., 2012). VH-IVUS allows the observation of the vessel wall, accounting for positive remodelling, or plaque expansive growth.

STEMI patients had significantly larger plaques with large EEL diameter and plaque area compared to the other groups of patients. No significant differences in lumen dimensions or area measurements were observed, suggesting that plaques of STEMI patients have an outward growth. Hence, plaque rupture appears to be related to plaque expansive growth, rather than to vessel stenosis. Similar observations were reported by Hong et al., (2012). Positive plaque remodelling was associated to thin cap fibroatheroma and plaque greater percentage of necrotic core, which were indicated as indexes of plaque vulnerability.

We also intended to evaluate the possible association between plaque morphological characteristics and TNF- α and ox-LDL circulation levels. TNF- α is involved in endothelial cell activation and in the inflammatory response. Increasing levels of this pro-inflammatory cytokine promotes a continuous systemic inflammatory stimulation that can trigger and amplify local inflammatory responses, hence expressing the extent of vascular inflammation. (Sano et al., 2006); (Böse et al., 2007) The association of TNF- α with EEL diameter – and not with lumen measurements – suggests that this cytokine may be a good indicator of plaque positive remodelling.

Extensive experimental data shows that ox-LDL is formed in the arterial wall contributing to the plaque progression. It is accepted that ox-LDL in circulation is originated in the vessel wall, being its circulating levels strongly associated to angiographically documented CAD (Napoleão et al., 2012). Increases in plaque area may favour plaque outflow and exposure to shear stress may contribute to endothelial denuding and plaque cap erosion, which leads to plaque rupture. (Greco et al., 2009); (Choi et al., 2010) Hence, the positive association of plaque area with ox-LDL concentrations in plasma can also be considered a marker of plaque instability.

6 CONCLUSIONS

The association of ox-LDL and TNF- α circulating levels with characteristics of plaque expansive growth indicate that these biomarkers may have a role in plaque activity expressing plaque vulnerability. The results suggest that these biomarkers have clinical implications for identifying vulnerable patients. Further studies are needed to evaluate the impact of ox-LDL, TNF- α , and VH-IVUS derived measures on clinical presentation.

ACKNOWLEDGEMENTS

The study was carried out under Fundação para a Ciência e Tecnologia PIC/IC/82734/2007 research contract.

REFERENCES

- Amato, M., Montorsi, P., Ravani, A., Oldani, E., Galli, S., Ravagnani, P. M., Tremoli, E., Baldassarre, D., 2007. Carotid intima-media thickness by B-mode ultrasound as surrogate of coronary atherosclerosis: correlation with quantitative coronary angiography and coronary intravascular ultrasound findings, *European Heart Journal* 28: 2094–2101.
- Böse, D., von Birgelen, C., Erbel, R., 2007. Intravascular Ultrasound for the Evaluation of Therapies Targeting Coronary Atherosclerosis, *J Am Coll Cardiol* 49:925–32.
- Choi, S. H., Chae, A., Miller, E., Messig, M., Ntanos, F., DeMaria, A. N., Nissen, S. E., Witztum, J. L., Tsimikas, S., 2008. Relationship Between Biomarkers of Oxidized Low-Density Lipoprotein, Statin Therapy, Quantitative Coronary Angiography, and Atheroma Volume, *J Am Coll Cardiol* 52: 24-32.
- Fayad, Z. A., Fuster, V., 2001. Clinical imaging of the high-risk or vulnerable atherosclerotic plaque, *Circ. Res.*; 89: 305-316.
- Goldstein, J. L., Ross, M. S., 1987. Regulation of low-density lipoprotein receptors: implications for pathogenesis and therapy of hypercholesterolemia and atherosclerosis, *Circulation* 76: 504-507.
- Greco, T. P., Conti-Kelly, A. M., Anthony, J. R., Greco, Jr. T., Doyle, R., Boisen, M., Kojima, K., Pharm, B. A., Matsuura, E., Lopez, L. R., 2010. Oxidized-LDL/ β 2-Glycoprotein I Complexes Are Associated With Disease Severity and Increased Risk for Adverse Outcomes in Patients With Acute Coronary Syndromes, *Am J Clin Pathol* 133:737-743.
- Greco, T. P., Conti-Kelly, A. M., Greco, Jr. T., Doyle, R., Matsuura, E., Anthony, J. R., Lopez, L. R., 2009. Newer Antiphospholipid Antibodies Predict Adverse Outcomes in Patients With Acute Coronary Syndrome, *Am J Clin Pathol* 132: 613-620.
- Hansson, G. K., 2005. Inflammation, Atherosclerosis, and Coronary Artery Disease, *N Engl J Med* 352:1685-95.
- Hoffmann, U., Moselewski, F., Nieman, K., Jang, I. K., Ferencik, M., Rahman, A. M., Cury, R. C., Abbara, S., Joneidi-Jafari, H., Achenbach, S., Brady, T.J., 2006. Noninvasive Assessment of Plaque Morphology and Composition in Culprit and Stable Lesions in Acute Coronary Syndrome and Stable Lesions in Stable Angina by Multidetector Computed Tomography, *Am Coll Cardiol* 47: 1655– 62.
- Hong, Y. J., Jeong, M. H., Choi, Y. H., Song, J. A., Ahmed, K., Lee, K. H., Kim, D. H., Lee, M. G., Park, K. H., Sim, D. S., Yoon, N. S., Yoon, H. J., Kim, K. H., Park, H. W., Kim, J. H., Ahn, Y., Cho, J. G., Park, J. C., Kang J. C., 2012. Positive remodeling is associated with vulnerable coronary plaque components regardless of clinical presentation: Virtual histology-intravascular ultrasound analysis. *Int J Cardiol* (published online).
- Napoleão, P., Selas, M., Ramos, C., Turkman, A., Andreozzi, V., Mota Carmo, M., Viegas-Crespo, A. M., Cruz Ferreira, R., Pinheiro, T., 2011. The Role of Inflammatory Biomarkers in the Assessment of Coronary Artery Disease. In: *Coronary Angiography - Advances in Noninvasive Imaging Approach for Evaluation of Coronary Artery Disease*: Ed: Baskot B.G., InTech. p281-314.
- Napoleão, P., Selas, M., Freixo, C., Mota Carmo, M., Viegas-Crespo, A. M., Cruz Ferreira, R., Pinheiro, T., 2012. T lymphocytes alterations are associated with oxidized LDL, troponin T, white blood cells and C-reactive protein during acute myocardial infarction. *Clinical Hemorheology and Microcirculation* (published online).
- Ramos, C., Napoleão, P., Cruz Ferreira, R., Fondinho, C., Selas, M., Mota Carmo, M., Crespo, A. M. Pinheiro, T., 2013. Relationship Between Ox-LDL, Immune Cells, Atheroma Dimensions and Angiographic Measurements Assessed by Coronary Angiography and Intravascular Ultrasound. In *What Should We Know About Prevented, Diagnostic, and*

Interventional Therapy in Coronary Artery Disease,
Ed: Baskot B.G., InTech.

Sano, K., Kawasaki, M., Ishihara, Y., Okubo, M.,
Tsuchiya, K., Nishigaki, K., Zhou, X., Minatoguchi,
S., Fujita, H., Fujiwara, H., 2006. Assessment of
Vulnerable Plaques Causing Acute Coronary
Syndrome Using Integrated Backscatter Intravascular
Ultrasound, *J Am Coll Cardiol* 47: 734–41.

