

Osteoclast and Osteoblast Quantity Change in Guinea Pig's Tooth Movement

Erliera¹, Aditya Rachmawati¹, Veranyca Chiuman¹

¹Orthodonti Department, Faculty of Dentistry, Universitas Sumatera Utara,
Alumni Street No. 2 Universitas Sumatera Utara, Medan, Indonesia

Keywords: Remodelling, Osteoclast, Osteoblast.

Abstract: An orthodontic treatment is defined by the quantity and the quality of the remodelling process including bone resorption by osteoclast, and deposition by osteoblast. The activities of osteoclast and osteoblast in orthodontic tooth movement can be seen by quantitative analysis done to the alveolar bone histologic tissue on guinea pig. The aim of this research is to observe when the cells' activities in orthodontic tooth movement reach its optimum to move the tooth. This is an experimental research which includes intervention and control groups. Guinea pigs were divided into five groups by the time they be observed and were given new separator on each session to produce continuous force. This research showed that osteoclast activities reach its maximum at day 7, whereas the osteoblast activities is at day 21. The amount of osteoclast cells in five timesperiod is not statistically different ($p=0,061$), while the amount of osteoblast cell is statistically different ($p=0,006$). The difference of osteoclast cells' amount in control groups is statistically different with the intervention group at day 28 ($p=0,028$), whereas the osteoblast is statistically different at day 7 ($p=0,015$). In conclusion, osteoclast cells reach its maximum amount at day 7, whereas the osteoblast at day 21. The amount of osteoclast cells was highly increased when the intervention begins and decreased significantly through the end of the research (day 28), whereas the amount of osteoblast cell in control group is decreased drastically when the force was being applied (day 7), and had started to increase after day 14.

1 INTRODUCTION

Orthodontic treatment is one of the treatments which is done in dentistry to achieve an aesthetic dentofacial appearance by correcting the inter-incisal alignment, producing a good occlusion, removing the arrangement of crowded and rotated teeth (Ardhana, 2013). The movement of teeth during orthodontic treatment causes an intercourse reaction between periodontal tissue, alveolar bone, and causes the release of certain substances from within the teeth and the systems around it (Ariffin, 2011). Histologically, the periodontal tissue receives forces which are generally known in orthodontic as pressure area, which is the area where the resorption of alveolar bone happens due to the pressure on periodontal ligament, and the tension area, which is the area where the formation of the alveolar bone takes place. Both of these forces are the ones that make the movement of teeth possible (Harry and Sandy, 2004).

The basic orthodontic treatment can be done by repositioning the teeth by either using fixed or

removable appliances (Hikmah, 2015). There are few concepts describing the mechanism of orthodontic tooth movement: pressure tension theory, blood flow theory, bone bending and piezoelectric theory (Bhalajhi, 2004). When an orthodontic force is applied, the space of periodontal ligament in the pressure area becomes smaller which causes vascular constriction, reduction of cells replication and collagen production, followed by resorption of the bone (Meikle, 2006). Whereas in the tension area, the space between periodontal ligament becomes wider, vascularization increases, replication of cell and production of collagen increases, thus causes deposition of bone (Graber and Vanarsdall, 2012).

Orthodontic tooth movement are divided into three phases: initial phase, lag phase, and post lag phase (Krishnan and Davidovitch, 2006). Initial phase is the phase which involves rapid movement of the teeth. This phase causes teeth to move inside the space of periodontal ligament and bending of alveolar bone (Ariffin, 2011). In lag phase, there are no movement of the teeth. But if it happens, it only

occurs in a short distance (Krishnan and Davidovitch, 2006). This movement is caused by the hyalinization tissue process of the periodontal ligament that receive force. The movement of teeth will not happen until the cell completely resorb the whole necrotic tissue area (Krishnan and Davidovitch, 2015). In post lag phase, the speed of tooth movement increases gradually. Tooth movement will reoccur after all the hyaline area is eliminated and then the resorption will then begin (Bhalajhi, 2004).

A successful orthodontic treatment is based on the remodelling process which involves the process of bone resorption by osteoclast, and bone deposition by osteoblast (Proffit, 2007). These processes are based on the quantity and quality of osteoclast and osteoblast (Hikmah, 2016). Boulpaep and boron (cit Kini and Nandeesh) stated that after putting the force on ligament periodontal for a few hours, osteoclast will be multiplied and resorption process will begin on the bone surface, whereas for the involving tension area, osteoblast will replicate and forms a new layer of bone. Based on this situation, a successful orthodontic treatment is based on the effectiveness of remodelling process, which is based on the quality and quantity of the osteoclast and osteoblast (Kini and Nandeesh, 2012).

Activation of osteoblast and osteoclast cells can be observed in a few ways: histology examination through pathology anatomy with biomarker protein coloring, or with the coloring of Hematoxylin Eosin (HE). Samples which are going to be examined is firstly fixated using formalin, then going through decalcification, dehydration, clearing, and embedding processes. Samples are then cut longitudinally by using microtom to identify the histologic image of osteoblast and osteoclast cell. Generally, cells that are analyzed histologically is done on guinea pig (*Cavia cobaya*) since it has high similarity to human biologically (Legendre, 2016).

2 MATERIAL AND METHOD

This research was approved by the ethics committee of Biology Department, University of Sumatera

Utara. Thirty guinea pigs weighing 250-400 grams aged 2-4 month were kept under standard condition 3 days before the research begins and were all in good condition during the experimental period. Guinea pig which lost the separator or die before the observation time is excluded in this research. Guinea pigs were randomly divided into five groups of 6 animals each: control group (no treatment), and four experimental groups (observed on day 7, 14, 21, and 28) and were then fitted with 0,5 mm Ormco elastomeric separator in the left maxilla incisors on day 0. The fitted separator is then removed and replaced with the new separator in both maxilla incisors on day 7 to produce continuous force. Six guinea pigs in each group were euthanized using 75 mg/kg ketamine on days 0, 7, 14, 21, and 28 after the orthodontic force is applied. After euthanasia, the anterior maxilla with two incisors were cutted longitudinally and fixed in a 10% buffered formalin solution for 24 hours. After washing with water, the specimens were dehydrated and embedded in paraffin. Slices measuring 4-6 µm in thickness were obtained and stained with haematoxylin- eosin. The quantitative analysis of osteoclast and osteoblast cells is then done by observing the histologic slide under microscope with 400x magnification. Cells count is done in five field of view to get the average value in each pressure and tension side and is done by two observers. Data were expressed as mean and standard deviation values. The data's normality was tested with Saphiro-Wilk and independent t test was done as an intern rater test. The data were then analyzed using Repeated Measurement Test of ANOVA.

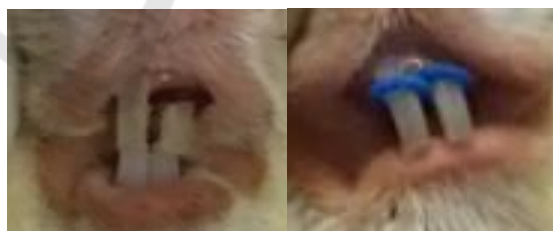


Figure 1: Placement of 0,5 mm Ormco elastomeric separator in the left maxilla incisor on day 0, and the replacement of new separator in both maxilla incisors on day 7, 14, and 21 to produce continuous force.

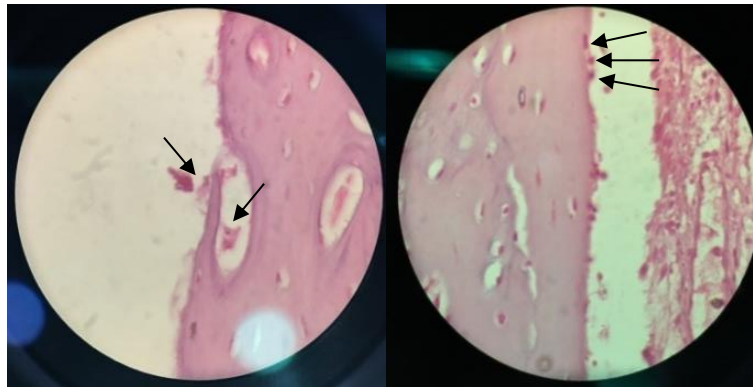


Figure 2: Microscopic view of osteoclast and osteoblast cells with 400x magnification.

3 RESULTS

Five guinea pigs were excluded from this study. Three guinea pigs died and the other two has been lost for the separator before observation time.

Saphiro Wilk is used as a normality test and resulting $p > 0,05$ indicates that the data were normally distributed. Independent t test showed no significant differences between the observers' data ($p > 0,05$).

Table 1: Osteoclast Cells Distribution in Five Timesperiod

Observation Time	Mean±SD
Day 0	0,64±0,26
Day 7	1,32±0,77
Day 14	1,20±1,03
Day 21	0,56±0,38
Day 28	0,32±0,36

Table 2: Osteoblast Cells Distribution in Five Timesperiod

Observation Time	Mean±SD
Day 0	7,04±0,36
Day 7	5,80±0,24
Day 14	6,04±0,90
Day 21	6,44±0,74
Day 28	5,04±0,93

Table 3: Osteoclast Quantity Differences of Five Timesperiod

Timesperiod (Days)	Mean Differences	Significance	p-value
0-7	+0,680	1,000	0,061
7-14	-0,120	1,000	
14-21	-0,640	1,000	
21-28	-0,240	1,000	

Table 4: Osteoblast Quantity Differences of Five Timesperiod

Timesperiod (Days)	Mean Differences	Significance	p-value
0-7	-1,240	0,015	0,006
7-14	+0,240	1,000	
14-21	+0,400	1,000	
21-28	-1,400	0,220	

Table 5: Quantity Differences of Osteoclast between Control and Experimental Groups

Days	Mean Differences	Significance
0	-0,680	1,000
7	-0,560	1,000
14	0,080	1,000
28	0,320	0,028

Table 6: Quantity Differences of Osteoblast between Control and Experimental Groups

Days	Mean Differences	Significance
0	1,240	0,015
7	1,000	0,601
14	0,600	1,000
28	2,000	0,232

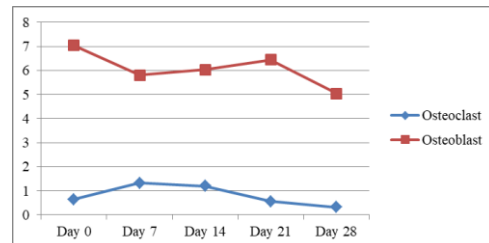


Figure 3: Activities of Osteoclast and Osteoblast

4 DISCUSSION

Figure 3 illustrate the activities of osteoclast and osteoblast on the pressure and tension side. The quantity of osteoblast cell found much more than the osteoclast cells. This result is corresponding with Sutantyo's research that state out osteoclast reactivity is not only based on the quantity, but also the quality of the cell itself (Patil and Jayade, 2006).

Table 1 and table 2 illustrate the osteoclast and osteoblast cells distribution in five times period. A number of osteoclast and osteoblast cell was observed on day 0, which prove that resorption and deposition of bone as a remodelling process always happen although no orthodontic force is given. A research by Miyoshi et al., state that control samples with no treatment undergone a physiologic bone remodelling process showed by the movement of the tooth (Patil and Jayade, 2006). Table 3 and table 4 illustrate the osteoclast and osteoblast quantity differences in five times period. Data analysis shows no significant differences of osteoclast quantity in five times period ($p=0,061$), but there were significant differences of osteoblast quantity ($p=0,006$). Table 5 and table 6 illustrate the quantity differences of osteoclast and osteoblast between control and experimental groups. Post Hoc test with Bonferroni correction showing significant differences of osteoclast cell quantity between control group and the group observed on days 28 ($p=0,028$), and significant differences of osteoblast cell quantity between control group and group observed on days 7 ($p=0,015$).

5 CONCLUSIONS

In conclusion, the finding of the present study show that the activities of osteoclast and osteoblast cells are not only depends on its quantity, but also its quality. The present study also concludes that cells' activities in orthodontic tooth movement reach its optimum to move the tooth in a cycle of less than 28 days as the osteoclast and osteoblast cells quantity will drop after days 28.

ACKNOWLEDGEMENTS

We are very extremely privileged this completion of our projects addressed to our Research Institution from Universitas Sumatera Utara at the expense of this study from TALENTA funding in year 2018 and our very great appreciation for

Hospital of University Sumatera Utara, Animal House of Biology's Department and Patology Anatomy Department from our beloved Universitas Sumatera Utara.

REFERENCES

- Ardhana, W., 2013, 'Identifikasi perawatan ortodontik spesialisik dan umum', *Maj Ked Gi*, vol. 20, no. 1, p. 232-7.
- Ariffin, SHZ., Yamamoto, Z., Abidin, IZZ., Wahab, RMA., Ariffin ZZ., 2011, 'Cellular and molecular changes in orthodontic tooth movement', *Sci World J*, vol. 11, p. 1788-803.
- Bhalajhi, SL., 2004, *The art and Science*, 3rd ed, New Delhi, Arya (MEDI) Publishing House.
- Graber, TM., Vanarsdall, RL., 2012, *Orthodontics current principles and techniques*, 5th ed, Missouri, Mosby.
- Harry, R., Sandy, J., 2004, 'Orthodontics. Part 11: Orthodontic tooth movement', *British Dent J*, vol. 196, no. 7, p. 391-4.
- Hikmah, N., 2015, 'Profil osteoblas dan osteoklas tulang alveolar pada model tikus diabetes tahap awal dengan aplikasi gaya ortodonti yang berbeda', *El-Hayah*, vol. 5, no. 2, p. 97-102.
- Hikmah, N., Dewi, A., Maulana, H., 2016, 'Rasio osteoklas dan osteoblas pada tulang alveolar model tikus diabetes dengan aplikasi gaya ortodonti', *Jurnal Ked Brawijaya*, vol. 29, no. 1, p. 54-8.
- Kini, U., Nandeesh, BN., 2012, *Physiology of bone formation, remodeling, and metabolism*. In: Fogelman et al (eds.). *Radionuclide and hybrid bone imaging*, Berlin, Springer.
- Krishnan, V., Davidovitch, Z., 2006, 'Cellular, molecular, and tissue-level reactions to orthodontic force', *Am J Orthod Dentofacial Orthop*, vol. 129, p. 1-32.
- Krishnan, V., Davidovitch, Z., 2015, *Biological mechanisms of tooth movement*, 2nd ed, Chichester, Wiley Blackwell.
- Legendre, L., 2016, *Anatomy and disorders of the oral cavity of guinea pigs*, Vancouver, Elsevier.
- Meikle, MC., 2006, 'The tissue, cellular, and molecular regulation of orthodontic tooth movement: 100 years after Carl Sandstedt', *European J Orthod*, vol. 28, p. 221-38.
- Patil, A., Jayade, VP., 2006, 'Advances in biology of orthodontic tooth movement – a review', *J Ind Orthod Soc*, vol. 39, p. 155-64.
- Proffit, WR., Fields, HW., Sarver, DM., 2007, *Contemporary orthodontics*, 4th ed, Missouri, Elsevier.