

Histopathologic Feature and Vitamin D Receptor Expression of Benign Breast Tumor

Mega Sari Sitorus¹, Dwi Rita Anggraini¹, Lita Feriyawati¹

¹Departement of Anatomy, Medical Faculty, Universitas Sumatera Utara

Keywords: VDR, Benign Breast Tumor, Fibroadenoma.

Abstract: Many studies say that vitamin D levels are useful as a protection that can decrease the risk of breast cancer, colon, prostate and ovarian cancers. But some say it's not related. But how the expression of benign breast tumor never been reported. The existence of VDR can be showed by its expression through immunohistochemistry. This report will describe the expression of VDR in benign breast tumor which the most is fibroadenoma mamma. Pathological tissue samples were obtained from 50 patients suffered with benign breast lesion that treated in Grandmed Hospital. There are 50 females, the mean age was 24,1, ranging from 12 to 42 years of age. All of the Hematoksilin Eosin staining slides are examined by pathologist using light microscope and concluded as fibroadenomas. The presence and location VDR is detected by immunostaining with VDR Antibody (D-6) from Santa Cruz Biotechnology. One of the most common benign tumors in the breast around 30 years old is fibroadenomas. In this study it is found that 34 patients (68%) under 30 years old. The expression of VDR in the fibroadenomas are strong : 42 tumours (82%), moderate: 4(8%, low: 3 (6%), negative: 1(2%). Most of them are VDR positif expression. From the figure 4 we can see that the VDR is placed in the nuclear dan cell membrane of the cells. Stromal cells doesn't show expression of VDR. This discribe that only epithelial cell of breast glandular this receptor.

1 INTRODUCTION

Usually, the tumor that grows in the breast are benign. Attention is more given to malignant breast lesion because breast cancer is the most common malignancy among women in the world. Actually, benign breast tumor are more frequent than malignant lesions (Guray, 2006). Fibroadenoma of the breast is a relatively frequently occurring tumor. It can occur in any age of women, but the peak incidence is in twenty until thirty years of age. Although often considered a benign tumor, several reports describe a higher risk of subsequent breast carcinoma in patients diagnosed with fibroadenoma (Kuijper, 2001).

The study during the two decades before has mentioned that the variety biological actions of 1,25-dihydroxyvitamin D₃ (1,25(OH)₂D₃/ Calcitriol) are triggered by exactly changes in gene expression which are assisted by intracellular vitamin D receptor (VDR)(Pike JW, 2010). Mostly of breast tumors (58%) displayed moderate to strong VDR expression. An aggressive tumor display inversely related to VDR expression (A-Azhri, 2017).

A fat soluble vitamin D consist of steroid molecular structures (Yosephine B, 2016). Sunlight exposure is the main source of vitamin D for human. Ultraviolet B light from the sun will penetrate the skin, change 7-dehydrocholesterol from keratinocytes and fibroblasts in plasma membranes to be previtamin D₃. In the plasma membrane, previtamin D₃ will be converted rapidly to vitamin D₃, then released into the extracellular space. In the skin Vitamin D₃ is bounded vitamin D-binding protein. While vitamin D₂ and vitamin D₃ from the diet therapy bound with vitamin D binding protein and lipoprotein. In the liver, vitamin D₂ and D₃ are hydroxylated to be 25-hydroxyvitamin D [25 (OH) D]. 25 (OH) D is the main form of circulation. This form molecule is used to measure the vitamin D status. 25 (OH) D is still inactive form and should be hydroxylized at carbon 1 to be 1,25-dihydroxyvitamin D [1,25 (OH) 2D/calcitriol] by the kidney and other tissues, including the breast (Katie MO, 2017).

1,25 (OH) 2D has endocrine role to control calcium metabolism by increasing absorption and mobilizing calcium from bone (Holick MF, 2018).

Other sources of vitamin D are very few gets from foods including oily fish, such as salmon, mackerel, tuna, and sardines. Vegetable foods generally contain low vitamin D. Now there are many kinds of foods which contain fortified vitamin D, particularly milk products, biscuits, orange juice, yogurt and cereals. Some foods, such as milk, bread, cereals, are fortified with vitamin D (Yosephine B, 2016; Holick MF, 2018).

Actions of 1,25(OH)₂D are mediated by the VDR. It consists of three domains: the C-terminal ligand binding domain, N-terminal DNA binding domain, and hinge region binding binds these two domains together (Bikle DD, 2014). VDR belongs to the nuclear subfamily receptors acts as transcription factors into the target cells after making a dimer with retinoid X receptors (RXR). After dimerization, the compound molecule binds to VDR(Gil A, 2018). In the intestine and bone this action to augment intestinal calcium absorption and influence osteoclast activity.

Prostate, colon, and breast express 1-hydroxylase, non-calcium regulating tissues locally convert 25(OH)D to 1,25(OH)₂D which regulate cell proliferation and differentiation, to possibly decrease the risk of cell transformation into a malignant lesion. Almost tissues and cells in the body have vitamin D receptor. The presence of 1,25(OH)₂D to be one of the most potent regulators of cellular growth in normal condition and cancer cells (Stechschulte SA, 2009).

Many studies say that vitamin D levels are useful as a protection that can decrease the risk of colon cancer, breast, prostate and ovarian cancers. But some say it's not related (Gil A, 2018). But how the expression of benign breast tumor never been reported.

The existence of VDR can be showed by its expression through immunohistochemistry. This report will describe the expression of VDR in benign breast tumor which the most is fibroadenoma mamma.

2 MATERIAL AND METHODS

Pathological tissue samples were obtained from 50 patients suffered with benign breast lesion that treated in Grandmed Hospital. There are 50 females, the mean age was 24,1, ranging from 12 to 42 years of age. All of the Hematoksilin Eosin staining slides are examined by pathologist using light microscope and concluded as fibroadenomas. The presence and location VDR is detected by immunostaining with VDR Antibody (D-6) from Santa Cruz Biotechnology.

Table 1: Characteristics of the patients.

| Age of patients with fibroadenoma mammae | |
|--|------------|
| 10–14 years | 2 (4.0%) |
| 15–19 years | 10 (20.0%) |
| 20–24 years | 18 (36.0%) |
| 25–29 years | 4 (8.0%) |
| 30–34 years | 7(14.0%) |
| 35–39 years | 5(10.0%) |
| 40–44 years | 4(8.0%) |

Immunohistochemistry and Evaluation

In this study, the samples are from formalin-fixed paraffin embedded pathological tissue. The VDR expression were studied by immunostaining using monoclonal antibodies VDR Antibody (D-6) from Santa Cruz Biotechnology, according the standards protocols used in laboratories of Murni Teguh Hospital .

VDR immunostaining intensity of fibroadenoma was examined semiquantitatively by two independent observers from 0 to 3 arbitrary units with 0 as negative (0), weak/low (1), moderate (2) and strong (Pike JW, 2010). VDR staining intensity in fibroadenoma lesions was evaluated with reference to intense reddish-pink basal layer of normal skin epidermis, scored as strong. Light reddish-pink and light pink stained cells were scored as cells with moderate or weak VDR expression, correspondingly. The VDR expression was assessed for cytoplasm and nuclei of cells separately (Brozyna AA, 2011).

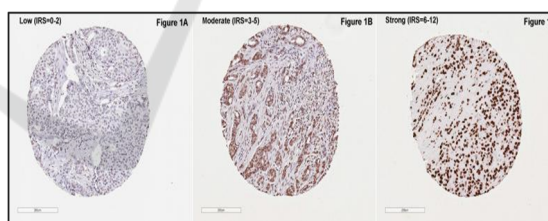


Figure 1: Representative images of vitamin D receptor (VDR) protein expression, classified by immunoreactive score (IRS) (Al-Zahri J, 2017).

3 RESULTS

The most common benign tumors of the breast in woman is fibroadenomas. This tumor usually attack woman under 30 years old. In this study it is found that 34 patients (68%) under 30 years old. Microscopically, fibroadenoma is a benign tumor with biphasic features consist of epithelial and stromal components (Lee M, 2015).

The microscopic features showed in figure 2. The tumour consists of epithelial component as a

glandular slit or tubular form and propiferative stromal component.

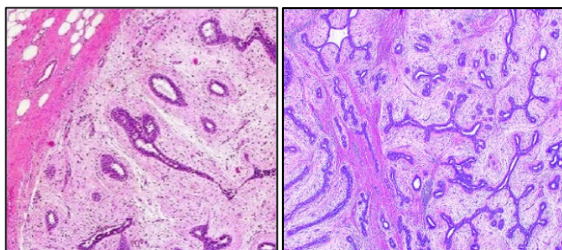


Figure 2: Pathologic view of fibroadenomas.

Most of the of fibroadenomas present as a single mass (70%). Others are as multiple masses around 10%–25%. Characteristic of fibroadenomas are a painless, mobile, smooth, and rubbery mass with distinct borders. The size usually ranging from 1 cm to 3 cm, on the upper outer quadrant of the breast. It can also be very small unpalpable mass that it is only seen on microscopic examination. Simetimes can be larger than 10 cm and may cause breast asymmetry and significant esthetic problem of the breast. The finding existence of VDR in other tissue beside gut and skeletal are observed in this study in benign breast tumor (figure 3).

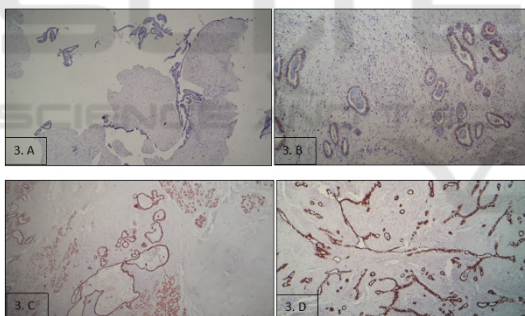


Figure 3. VDR expressions in fibroadenomas, A. Negative, B. Low, C. Moderate, E. Strong (100x).

4 DISCUSSION

Fibroadenomas is the most benign breast tumour in woman. Usually they are found in young middle age, below 30 years old. In this study found that 68% tumours are found under 30 years old. As a benign breast tumor, fibroadenoma is also thought to represent a set of hyperplastic breast lobules called “aberrations of normal development and involution”. This lesion is a hormone-dependent neoplasm that lactates during pregnancy and also get involuting along with the rest of the breast in perimenopause.

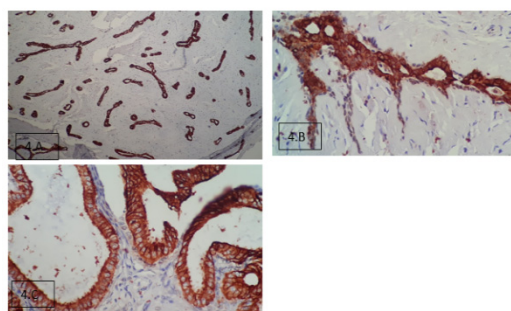


Figure 4. Distribution of VDR Expression (100x).

The expression of VDR in the fibroadenomas are strong : 42 tumours (82%), moderate: 4(8%, low: 3 (6%), negative: 1(2%). Most of them are VDR positif expression. From the figure 4 we can see that the VDR is placed in the nuclear dan cell membrane of the cells. Stromal cells doesn’t show expression of VDR. This discribe that only epithelial cell of breast glandular this receptor.

5 CONCLUSION

The histopathologic feature of benign breast tumor mostly is fibroadenoma mammae. The glandular dan stromal cells proliferates resemble the cleft like appearance. With imunohistochemistry can detect that vitamin D receptor also expressed in the epithelial cells, both in nuclei and cytoplasm.

REFERENCES

- Al-Azhri J, Zhang Y, Bshara W, Zirpoli G, McCann SE, Khoury T Morrison CD, Edge SB, Ambrosone CB, Yao S. 2017. Tumor Expression of Vitamin D Receptor and Breast Cancer Histopathological Characteristics and Prognosis. *Clin Cancer Res*, 1;23(1):97-103.
- Bikle DD, 2014. Vitamin D Metabolism, Mechanism of Action, and Clinical Applications. *Chem Biol*; 21(3): 319–329.
- Brożyna AA, Jozwicki W, Janjetovic Z, Slominski AT. 2011. Expression of vitamin D receptor (VDR) decreases during progression of pigmented skin lesions. *Hum Pathol.* ; 42(5): 618–631.
- Gil A, Plaza-Diaz J, Mesa MD. 2018. Vitamin D: Classic and Novel Actions. *Ann Nutr Metab*;72:87–95.
- Guray DM, Sah AA. 2006. Benign Breast Diseases: Classification, Diagnosis, and Management. *The Oncologist*;11:435–449.
- Holick MF. 2018. Vitamin D and Sunlight: Strategies for Cancer Prevention and Other Health Benefits. *Clinical Journal of the American Society of Nephrology*;3(5):1548-1554.

- Katie MO, Brien, Sandler DP, Taylor JA, Weinberg CR. 2017. Serum Vitamin D and Risk of Breast Cancer within Five Years. *Environmental Health Perspectives*; 077004(1-9). is available at <https://doi.org/10.1289/EHP943>.
- Kuijper A, Mommers EC, van der Wall E, van Diest PJ. 2001. Histopathology of Fibroadenoma of the Breast. *Am J Clin Pathol*;115:736-742.
- Lee M, Soltanian HT, 2015. Breast fibroadenomas in adolescents: current perspectives. *Adolesc Health Med Ther*;6:159–163.
- Pike JW, Meyer MB. 2010. The Vitamin D Receptor: New Paradigms for the Regulation of Gene Expression by 1,25-Dihydroxyvitamin D₃. *Endocrinol Metab Clin North Am.*; 39(2): 255–269.
- Steckschulte SA, Kirsner RS, Federman DG. 2009. Vitamin D: Bone and Beyond, Rationale and Recommendations for Supplementation. *The American Journal of Medicine*;122(9): 793-802.
- Yosephin B , Anwar F, Riyadi H, Khomsan A, Elly N. 2016. Food Sources Of Vitamin D And Its Deficiency In Worker Women. *4th Asian Academic Society International Conference (AASIC)*;233-239. Available at https://www.researchgate.net/publication/306392153_food_sources_of_vitamin_d_and_its_deficiency_in_worker_women.

SCITEPRESS
SCIENCE AND TECHNOLOGY PUBLICATIONS