

# Nail Changes in Children Undergoing Chemotherapy

Ardelia Dyah Ayu<sup>1,\*</sup>, Reti Anggraeni<sup>1</sup>, Endra Yustin Ellista Sari<sup>1</sup>, Muh. Riza<sup>2</sup>, and Suci Widhiati<sup>1</sup>

<sup>1</sup>*Dermatovenereology Departement, Dr. Moewardi General Hospital/Faculty of Medicine Sebelas Maret University, Surakarta*

<sup>2</sup>*Pediatric Department, Dr. Moewardi General Hospital/ Faculty of Medicine Sebelas Maret University, Surakarta*

**Keywords:** nail changes, nail disorder, children, chemotherapy

**Abstract:** Many chemotherapeutic agents used in the management of various malignancies. Nail changes are often under recognized or attributed to other causes. The anticancer chemotherapeutic agents were known to cause a damage to the nail. This analytical, cross-sectional study was conducted in Dr. Moewardi General Hospital Surakarta between December 2017 and January 2018. The subjects were taken by consecutive sampling, consisting of 30 children undergoing chemotherapy and 30 healthy children as a control. History taking and physical examination in the form of digital photography as well as dermoscopic examination were conducted in all subjects. The data obtained were then analyzed using Mann-Whitney test,  $p < 0.05$  was considered significant statistically. Nail changes were observed in 25/30 ( 83.3%) of the children receiving chemotherapy and they have a statistical significant difference compared to control group, with the  $p$  value 0.000. The nail changes obtained were trachonychia (22,2%), dyschromia (18.5%), melanonychia (14.8%), and Beau's lines (14.8%). Combination of methotrexate and vincristine was the most frequent chemotherapeutic agent used in the subjects (40%). This study is expected to provide knowledge for dermatologist so that it can improve the promotive health, preventive, curative and education for the patient.

## 1 INTRODUCTION

The anticancer chemotherapeutic agents were known to cause various mucocutaneous side effects, including nail changes. Nail changes are often under-recognized or attributed to many causes. Chemotherapy-induced nail changes, though they not life threatening, are cosmetically distracting and can be a source of significant distress to patients.

The anti- cancer chemotherapeutic agents may cause a damage to the nail matrix or the nail bed and a variety of changes involving the nail plate, nail bed, hyponychium or the nail folds may be seen (Chen et al., 2007). Several chemotherapy agents and their combinations have been reported to induce nail changes, including taxoids, cyclophosphamide, doxorubicin/ daunorubicin, 5-fluorouracil and vincristine. Cyclophosphamide and doxorubicin are two agents commonly reported to affect the nails (Hinds & Thomas, 2008).

The nail changes mostly are the result of acute toxicity to the nail epithelium. Various symptoms will occur depend on which nail structure is affected and the severity of the insult (Piraccini et al., 2003). Pigmentation changes due to chemotherapeutic agents involving the nail plate are seen secondary to

the damage of the nail matrix melanocytes. The damage to the nail bed may be as a consequence of direct damage due to drugs or an indirect damage to the underlying blood vessels (Reddy et al., 2017).

Nail growth in children is faster than is in adult, and it is estimated to be at a rate of 0.12 mm / day (Chen et al., 2007; Balgord & Pardee, 2008; Robert et al., 2015). However, nail changes in children undergoing chemotherapy, in comparison to adult cases, are less well characterized in the literature. This study was designed to understand and to find out the pattern of nail changes in children receiving various chemotherapies.

## 2 METHODS

An analytical, cross-sectional study conducted in Dr. Moewardi General Hospital Surakarta between December 2017 and January 2018. The subjects were taken by consecutive sampling, consisting of 30 children undergoing chemotherapy and 30 healthy children as a control.

History taking and physical examination in the form of digital photography as well as dermoscopic

examination were conducted in all subjects. We excluded children with nail abnormalities which occur prior to chemotherapy. Potassium hydroxite (KOH) test was performed if there was a suspicion of onychomycosis and or its coincidence in the subjects. The data obtained were then analyzed using Mann-Whitney test,  $p < 0.05$  was considered significant statistically.

The data obtained were than analyzed using Mann-Whitney test. It is showed that there was a statistically significant difference in nail changes between children undergoing chemotherapy and healthy control group, with the  $p$  value 0.016. The age of most subject is between 6 – 11 years old. The number of men and women in this study was proportional.

### 3 RESULTS

Table 1. Clinical features of the enrolled subjects

	Total (chemotherapy group, n = 30) (control group, n = 30)	Percentage (%)
Age (year)		
0 – 5	15	25
6 – 11	41	68.3
12 - 16	4	6.7
Gender		
Male	28	46.7
Female	32	53.3
Nail changes in chemotherapy group	25	83.3
Yes	5	16.7
No		
Nail changes in control group	3	10
Yes	3	10
No	27	90

### 4 DISCUSSION

Nail dermoscopy (onychoscopy) has initially been used for the assessment of nail pigmentation, but its exertion has expanded for the diagnosis of all nail disorders and it becomes a routine diagnostic instrument, as it reveals helpful information. Dermoscopy can be applied to all visible parts of the nail unit, and even the nail matrix can be studied. Many nail signs can be magnified by dermoscopy and combined with clinical examination to establish the diagnosis (Piraccini et al., 2012). In this study we used dermoscopy examination to asses the diagnosis of the nail changes, combining with history taking and other physical examination.

Numerous mucocutaneous effects result from inflammatory disorder, systemic drugs, trauma, viral infection, macronutrient and micronutrients deficiency, and even product used on the nails (Kristien, 2015). Three out of 30 children in control group had nail changes, in the forms of Beau’s lines and leukonychia. These may occur due to nutritional deficiency in children, especially micronutrient deficiency.

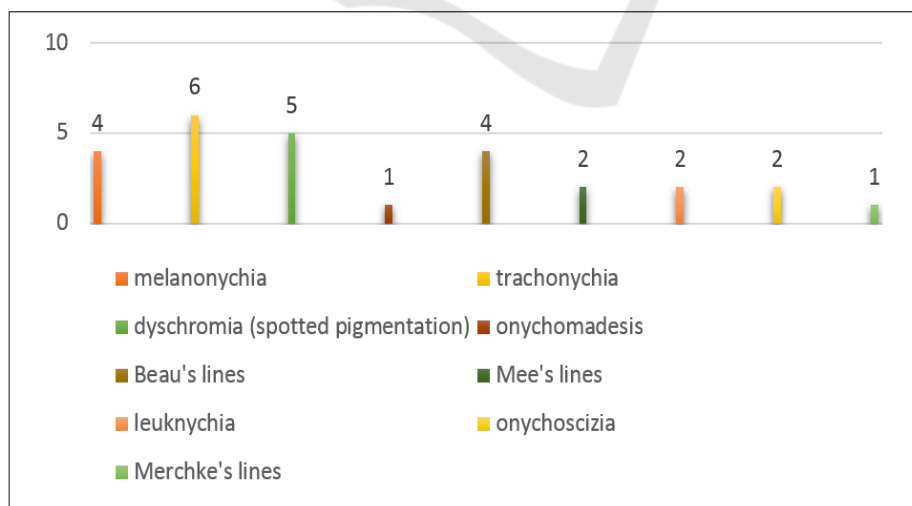


Figure 1. Pattern of nail changes in chemotherapy group

Figure 2. A. Trachonychia, change in nail plate. B. Melanonychia, change in nail pigmentation.

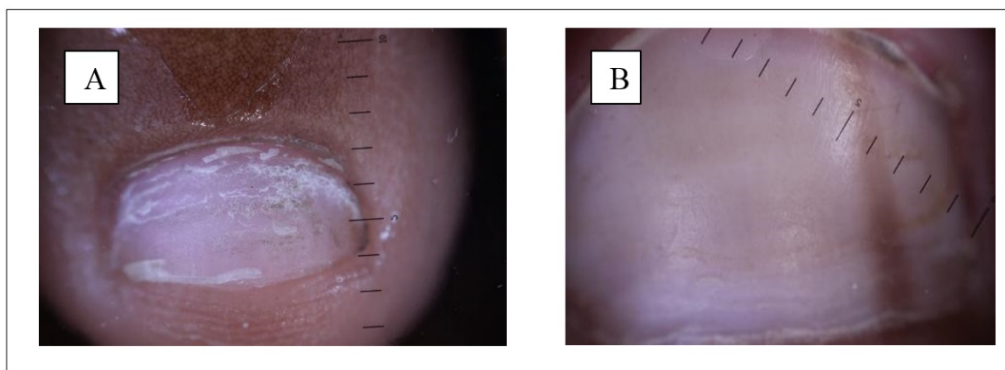


Table 3. The frequency of nail changes based on chemotherapy agents.

Agents of Chemotherapy	Frequency	Percentage (%)
Methotrexate + vincristine	10	40
Etoposide+ carboplatin	8	32
Doxorubicin + vincristine + cyclophosphamide	1	4
Cyclophosphamide	3	12
Cyclophosphamide + metilprednisolone	1	4
Vincristine	1	4
Cisplatin + bleomycine + vincristine	1	4

Nail changes were observed in 25/30 ( 83.3%) of the children receiving chemotherapy and have a statistically significance difference to control group. MEDLINE and EMBASE (1966–2008) databases reported that nail changes were caused by nail toxicity which is the adverse effect linked to a number of chemotherapeutic agents. The continuously dividing nail matrix cells are easily perturbed by antimetabolic activity so that chemotherapy agents become easier to affect the nails (Gilbar et al., 2009). Nail changes are usually temporary and resolve with the cessation of this therapy , but some may persist (Gupta et al., 2008).

Chemotherapy-induced nail changes can classified into nail color changes, changes in the surface of the nail plate, disruption between the nail plate and the underlying nail bed, and damage to soft tissue structures surrounding the nail (Ranawaka, 2009). In this study, nail color changes occur in 40.7% subjects and the rest are nail plate changes. The three most common nail changes found in our study were trachonychia, dyschromia, and melanonychia. Trachonychia is defined as roughness of the nails. Trachonychia has been grouped into 2 types: shiny trachonychia and opaque trachonychia, as seen in Figure 2.A; this likely represent the spectrum of disease severity. The clinical features of trachonychia include a sandpaperlike appearance of the nails, longitudinal ridging, brittleness, and nail pitting (Chu & Rubin, 2014).

Rough and brittle nails are caused by decrease in the nail growth rate, which is common in chemotherapy course. Trachonychia also have been suggested to be caused by underlying poor metabolic or nutritional health of patients with advanced cancers, but this suggestion has not been formally proven (Robert et al., 2015).

Nail hyperpigmentation can be brown or black (melanonychia) or other colours. It commonly presents as a longitudinal streak (longitudinal melanonychia) as seen in Figure 2.B, but can also present as a transverse band (transverse melanonychia), spotted pigmentation or involve the entire nail plate (total melanonychia) (Chu & Rubin, 2014). The exact mechanism of chemotherapy-induced hyperpigmentation is not clearly understood. But it is postulated that the accumulation of the drug in the nails can have a direct toxic effect on the melanocyte causing increased melanin production, or there may be an associated increase in the adrenocorticotrophic hormone or the melanocyte stimulating hormone.<sup>13</sup> Praveen Kumar et all in their study stated that the statistically significant changes observed were nail matrix melanocyte changes including longitudinal pigmentary bands as the most common change in 67.7% of cases, following administration of chemotherapy agents with an average onset of 6 weeks from the start of the course (Reddy et al., 2017).

Beau's lines are transverse linear depressions in the dorsum nail plate that emerge from beneath the proximal nail fold, and are due to a transitory decrease in mitotic activity of the nail matrix keratinocytes. Drug-induced Beau's lines are usually dose related and reproducible with readministration of the drug (Piraccini et al., 2003).

Most of the children (80%) in our chemotherapy group have undergone 0-6 month course duration. Drug-induced nail changes could develop within 3-4 weeks after the initiation of chemotherapy and sometimes they does not need specific treatment, because they show only past damage to the matrix and the changes generally resolve as the nails grow out (Robert et al., 2015). This also explains why in some subjects who have undergone a long course of chemotherapy may not develop any nail changes.

In our study methotrexate and vincristine were the most common combinations of chemotherapeutic agents used on the subjects (40%) and also the most frequent agents caused the nail abnormality. Loose toenails, thickened and discolorization, as well as onycholysis and nail shedding will occur correspond to chemotherapeutic cycles of methotrexate. In the other hand, vincristine has been reported to produce leukonychia, Beau's lines, Mees' lines, and onychodermal bands (Gilbar et al., 2009).

The evaluation of nail changes in children undergoing chemotherapy was hampered by some confounding factors, such as a combination of multiple agents in most regimens made it difficult to determine the main culprit drug, opportunistic infection during chemotherapy, and symptoms often resolve with or without drug withdrawal.

## 5 CONCLUSION

This study was conducted in Dr. Moewardi General Hospital Surakarta between December 2017 and January 2018. The statistical analysis revealed that there was a significant difference in nail changes between children undergoing chemotherapy and healthy control group, with the p value < 0.05. The most common nail changes was trachonychia. The combination of methotrexate and vincristine was the most frequent chemotherapeutic agent used in the subjects. The relationship between exposure time of chemotherapy agents or its combination with the onset of nail changes cannot be determined yet due to limited observation of time time research. Research with a larger number of subjects and longer observation time is needed to obtain more representative results and causative relationships between each parameters.

## REFERENCES

- Balgord, S., & Pardee, T., 2008. Chemotherapy-Induced Fingernail Changes. *Indian J Dermatol* [Internet], 53(4):204–205. Available from: <http://www.ncbi.nlm.nih.gov/pubmed/24795111>.
- Chen, W., Yu, Y. S., Liu, Y. H., Sheen, J. M., & Hsiao, C. C., 2007. Nail changes associated with chemotherapy in children. *Journal of the European Academy of Dermatology and Venereology*, 21(2), pp. 186-190.
- Chu, D. H., & Rubin, A. I., 2014. Diagnosis and management of nail disorders in children. *Pediatric Clinics*, 61(2), pp. 293-308, Available from: <http://linkinghub.elsevier.com/retrieve/pii/S0031395513002083>.
- Gilbar, P., Hain, A., & Peereboom, V. M., 2009. Nail toxicity induced by cancer chemotherapy. *Journal of Oncology Pharmacy Practice*, 15(3), pp. 143-155.
- Gupta, A., Parakh, A., & Dubey, A. P., 2008. Chemotherapy induced nail changes. *Indian journal of dermatology*, 53(4), pp. 204.
- Hinds, G., & Thomas, V. D., 2008. Malignancy and cancer treatment-related hair and nail changes. *Dermatologic clinics*, 26(1), pp. 59-68.
- Issaivanan, M., & Khairkar, P. H., 2003. Doxorubicin induced melanonychia. *Indian pediatrics*, 40(11), pp. 1094-1096.
- Kristien Hoffman., 2015. *When vitamin and nutritional deficiencies cause skin and nail changes*. Podiatry Today. [cited 29 January 2018]. Available from: <https://www.podiatrytoday.com/when-vitamin-and-nutritional-deficiencies-cause-skin-and-nail-changes>
- Piraccini, B. M., Bruni, F., & Starace, M., 2012. Dermoscopy of non-skin cancer nail disorders. *Dermatologic therapy*, 25(6), pp. 594-602.
- Piraccini, B. M., Iorizzo, M., & Tosti, A., 2003. Drug-induced nail abnormalities. *American journal of clinical dermatology*, 4(1), pp. 31-37.
- Ranawaka, R. R., 2009. Patterns of chromonychia during chemotherapy in patients with skin type V and outcome after 1 year of follow-up. *Clinical and Experimental Dermatology: Clinical dermatology*, 34(8), e920-e926.
- Reddy, P. K. S., Prasad, A. L. S., Sumathy, T. K., & Reddy, R. V., 2017. Nail changes in patients undergoing cancer chemotherapy. *International Journal of Research in Dermatology*, 3(1), pp. 49-54, Available from: <http://www.ijord.com/index.php/ijord/article/view/96>.
- Robert, C., Sibaud, V., Mateus, C., Verschoore, M., Charles, C., Lanoy, E., & Baran, R., 2015. Nail toxicities induced by systemic anticancer treatments. *The Lancet Oncology*, 16(4), e181-e189, Available from: [http://dx.doi.org/10.1016/S1470-2045\(14\)71133-7](http://dx.doi.org/10.1016/S1470-2045(14)71133-7).