

Bullous Pemphigoid Established by Direct Immunofluorescence: Case Report

Vidyani Adiningtyas, Hasnikmah Mappamasing, Septiana Widyantari, Trisiswati Indranarum, Sawitri, Evy Ervianti, Sunarko Martodiharjo, Dwi Murtiastutik

Department of Dermatology and Venereology, Faculty of Medicine, Universitas Airlangga / Dr. Soetomo General Hospital Surabaya

Keywords: bullous pemphigoid, autoimmune, subepidermal blistering, direct immunofluorescence, anti-BP180/230.

Abstract: Bullous pemphigoid (BP) is the most common autoimmune subepidermal blistering disease of the skin and mucous membranes. It is characterized by autoantibodies against hemidesmosomal proteins of the skin and mucous membranes. Collagen XVII and dystonin-e have been identified as target antigens. BP is usually a chronic disease, with spontaneous exacerbations and remissions. The diagnosis of BP relies on immunopathologic findings, especially based on both direct and indirect immunofluorescence microscopy observations, as well as on anti-BP180/BP230 enzyme-linked immunosorbent assays (ELISAs). The primary objectives are therefore to control both the skin eruption and itch, as well as to minimize any serious side-effects of the treatment.

1 INTRODUCTION

Bullous pemphigoid affects mostly the elderly (Wojnarowska et al., 2002; Di Zenzo et al., 2012). The incidence of the disease is increasing gradually and is associated with high morbidity and mortality. Clinically, BP is characterized by an intensely pruritic eruption with widespread bullous lesions. The clinical diagnosis can be challenging in the setting of atypical presentations. Both the morbidity of bullous pemphigoid and its impact on quality of life are significant (Bernard et al., 2017). Treatment is mainly based on topical and/or systemic glucocorticoids, but anti-inflammatory antibiotics and steroid sparing adjuvants are useful alternatives. Localized and mild BP can be treated with topical corticosteroids alone (Bastuji-Garin et al., 2011; Culton et al., 2012). Specifically, the goals of the management are: (i) to treat the skin eruption, reduce itching and prevent/reduce the risk of recurrence; (ii) to improve the quality of life of patients; and (iii) to limit the side-effects related to the newly introduced drugs, particularly in the elderly (Wojnarowska et al., 2002; Schmidt et al., 2012).

2 CASE

This case involved a 74 year-old male, whose chief complaint consisted of pain and erosions all over his body. This had been occurring for two weeks. Previously – one month earlier – there had been tense blisters on his chest, containing clear fluid. These were not easily broken but several of the blisters became eroded and pain was present in the eroded skin. Itchiness was minimal. There was no odour and no wound on the lips or genitalia. The patient also had a history of diabetes mellitus. His routine activity was cycling in the morning until noon. Dermatological examination revealed tense seropurulent bullae on non-sharply marginated erythematous macule. Bullae size varied from small to 2cm. Despite some erosion and thin scales, there was negative Nikolsky sign, no mousy odour and no lesions on the genitalia or lips. Upon the patient's admission, blood, urinary, electrolyte, liver and renal function tests were all performed and found to be within normal limits. Albumin, eosinophil and random blood glucose were abnormal. From the histopathological examination, the result was bullous pemphigoid and the direct immunofluorescent test found linear IgG and C3 in the basal membrane zone. The patient was treated

with methylprednisolone 4mg 3x16mg and dapsone 1x100mg daily, tapering off the steroid after there were signs of clinical improvement including no new lesions.

3 DISCUSSION

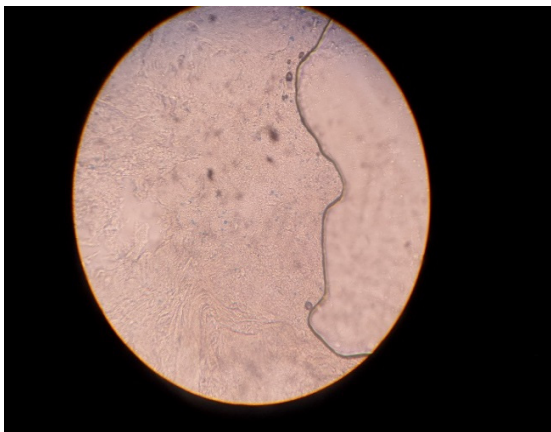


Figure 1: Gram staining reveals leukocyte only, without any coccus

The name ‘bullous pemphigoid’ (BP) is a pleonasm, as ‘pemphigoid’ is derived from Greek and means ‘form of a blister’ (pemphix, blister, and eidos, form) (Feliciani et al., 2015).

Bullous pemphigoid typically occurs in patients over 60 years of age, with a peak incidence occurring among those patients in their 70s. There are several reports of bullous pemphigoid in infants and children, although this is rare (Wojnarowska et al., 2002; Culton et al., 2012; Di Zenzo et al., 2012; Bernand & Antonicelli, 2017). This is consistent with the patient in our case; he is 74 years old. Old age is the major risk factor for the occurrence of BP.

Most cases of bullous pemphigoid occur spontaneously without any obvious precipitating factors. However, there are several reports in which bullous pemphigoid appears to be triggered by ultraviolet (UV) light, either UVB or following PUVA therapy, and radiation therapy. Certain medications have also been associated with the development of bullous pemphigoid including penicillamine, efalizumab, etanercept, and furosemide (Batsuji-Garin et al., 2011; Culton et al., 2012; Bernand & Antonicelli, 2017).

Since the patient stated that he routinely cycles every morning until 10am and never wears a hat or

applies sun protection, we suggest that one possible trigger might be UV light. In addition, various autoimmune disorders, psoriasis, and neurologic disorders have also been described in association with BP (Lipsker & Borradori et al., 2010; Venning et al., 2012).

The patient’s chief complaint consisted of blisters, erosion and pain on his body. Upon examination, tense bullae on erythematous macule were discovered. These were non-sharply margined, contained clear fluid, were not easily ruptured and were Nikolsky- and Asboe Hansen-sign negative. Eroded skin was widespread on the body from the ruptured blister; crust, scales and xerosis were also discernible on the body. This is consistent with the literature: clinical criteria BP typically presents with tense, mostly clear skin blisters, in conjunction with erythematous or urticarial plaques that are associated with moderate to severe pruritus.⁴ Although the pruritus was minimal in this patient. pruritus may be intense in some patients, but minimal in others. These lesions are most commonly found on flexural surfaces such as the lower abdomen and thighs, although they may occur anywhere (Culton et al., 2012). Predilection sites in the patient include the limbs and abdomen. The mucosae of eyes, nose, pharynx, oesophagus and anogenital areas are rarely affected (Culton et al., 2012; Venning et al., 2012).

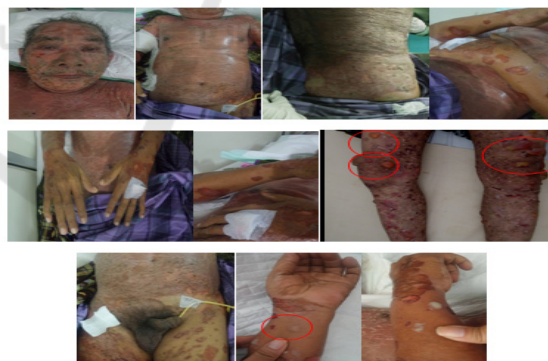

Figure 2: on regio cruris dextra et sinistra: tense blisters on erythematous macule; these were non-sharply margined, contained clear fluid and were not easy to break. Nikolsky- and Asboe Hansen-signs were negative. Erosion, scales and crust were found.

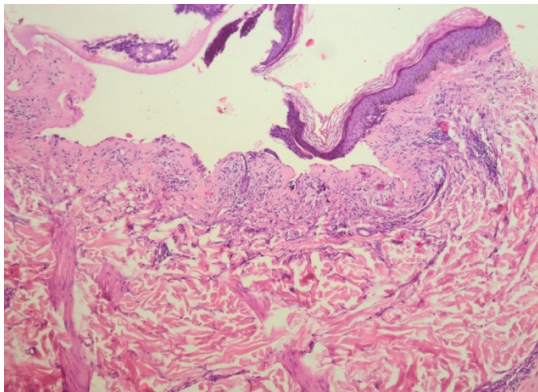


Figure 3. Histopathology examination with hematoeosin staining, subepidermal blister with with inflammatory infiltrate numerous eosinophil and several neutrophil, 100x magnification.

The hallmarks of bullous pemphigoid include the presence of subepidermal blisters, lesional and perilesional polymorphonuclear cell infiltrates in the upper dermis and immunoglobulin (Ig) G autoantibodies and C3 bound to the dermal epidermal junction. Direct IF of perilesional skin shows linear IgG (usually IgG1 and IgG4, although all IgG subclasses and IgE have been reported) and C3 along the basement membrane (Venning et al., 2012; Zhao & Murrell, 2015).

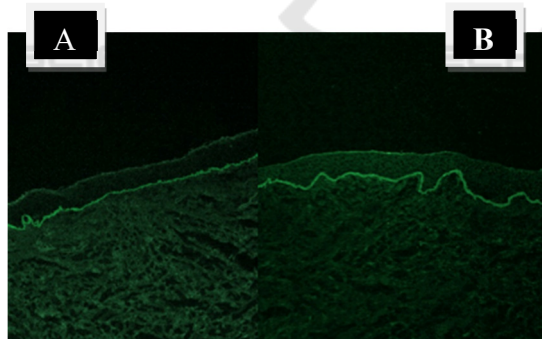


Figure 4: Direct immunofluorescence examination. A. C3 B. IgG

Diagnosis was made from anamnesis, physical examination, laboratory examination, histopathology and direct immunofluorescence. The diagnosis in this patient was bullous pemphigoid, hypoalbuminemia and diabetes mellitus (DM) type 2.

Treatment was immediately started: methylprednisolone 4mg in oral dosage 3 times 3 tablets daily (12mg-12mg-12mg) tapering off depending on the progression of the lesion to find maintenance dosage; dapsone 100mg once daily;

wound dressing using NaCl 0.9% on erosion lesion; insulin injection as advised from internal medicine department; insulin novorapid injection 3x6iu; insulin levemir 1x8iu morning dosage only; backup insulin 2iu with every 12mg methylprednisolone; Vitamin D 300iu; calcium carbonat 600mg; diet B1 2100kcal/day; and high protein diet for the hypoalbuminemia.

4 CONCLUSION

The diagnosis of bullous pemphigoid is made based upon clinical, histologic, and immunofluorescence (IF) features (Schmidt & Groves, 2016). The initial evaluation of patients should encompass a complete physical examination and, wherever possible, the assessment of the initial damage (Bernard & Antonicelli, 2017).

For decades, systemic corticosteroids have been used and considered as the gold standard for the treatment of this disease, especially for generalized BP (Schmidt et al., 2016). Immunosuppressive therapy with corticosteroid-sparing effects should be considered a second-line therapy when corticosteroids alone fail to control the disease, or in cases of contraindications to oral corticosteroids and comorbidities (such as diabetes, severe osteoporosis and cardiovascular disorders) (Bower, 2010). Unless glucose-6-phosphate dehydrogenase deficiency is evident, the use of dapsone (up to 1.5 mg/kg/day orally) may also be warranted, generally in association with topical or systemic corticosteroids, especially in the presence of mucosal involvement. In elderly patients, the complications of systemic glucocorticoid therapy (such as osteoporosis, diabetes, and immunosuppression) may be especially severe (Bouscarat et al., 2006; Bağcı et al., 2017). Therefore, it is important to try to minimize the total dose and duration of therapy with oral glucocorticoids (Culton et al., 2012; Bernard & Antonicelli, 2017).

REFERENCES

- Bağcı, I.S., Horváth, O.N., Ruzicka, T., Sárdy, M., 2017. Bullous pemphigoid. *Autoimmunity Reviews*. doi:10.1016/j.autrev.2017.03.010
- Bastuji-Garin, S., Joly, P., Lemordant, P., Sparsa, A., Bedane, C., Delaporte, E., Roujeau, J.C., Bernard, P., Guillaume, J.C., Ingen-Housz-Oro, S., Maillard, H., Pauwels, C., Picard-Dahan, C., Dutronc, Y., Richard, M.A., French Study Grp Bullous, D., 2011. Risk

- Factors for Bullous Pemphigoid in the Elderly: A Prospective Case-Control Study. *Journal of Investigative Dermatology* 131, 637–643. doi:10.1038/jid.2010.301
- Bernard, P., Antonicelli, F., 2017. Bullous Pemphigoid: A Review of its Diagnosis, Associations and Treatment. *American Journal of Clinical Dermatology*. doi:10.1007/s40257-017-0264-2
- Bouscarat, F., Chosidow, O., Picard-Dahan, C., Sakiz, V., Crickx, B., Prost, C., Roujeau, J.C., Revuz, J., Belaich, S., 1996. Treatment of bullous pemphigoid with dapsone: Retrospective study of thirty-six cases. *Journal of the American Academy of Dermatology* 34, 683–684. doi:10.1016/S0190-9622(96)80085-5
- Bower, C. 2010. Bullous pemphigoid: guide to diagnosis and treatment. *Prescriber*. 17(12):44-50.
- Culton, D.A., Diaz, L.A., Liu, Z. 2012. Bullous pemphigoid. In: Goldsmith L. Fitzpatrick T(ed). *Fitzpatrick's dermatology in general medicine*. 1st ed. New York: McGraw-Hill Medical. doi:10.1017/CBO9781107415324.004 P 608-16
- Di Zenzo, G., della Torre, R., Zambruno, G., Borradori, L., 2012. Bullous pemphigoid: From the clinic to the bench. *Clinics in Dermatology* 30, 3–16. doi:10.1016/j.clindermatol.2011.03.005
- Feliciani, C., Joly, P., Jonkman, M.F., Zambruno, G., Zillikens, D., Ioannides, D., Kowalewski, C., Jedlickova, H., Kárpáti, S., Marinovic, B., Mimouni, D., Uzun, S., Yayli, S., Hertl, M., Borradori, L., 2015. Management of bullous pemphigoid: The European Dermatology Forum consensus in collaboration with the European Academy of Dermatology and Venereology. *British Journal of Dermatology* 172, 867–877. doi:10.1111/bjd.13717
- Lipsker, D., Borradori, L. 2010. 'Bullous' Pemphigoid: What Are You? Urgent Need of *Definitions and Diagnostic Criteria*. *Dermatology*. 221(2):131-134.
- Schmidt, E., della Torre, R., Borradori, L., 2012. Clinical Features and Practical Diagnosis of Bullous Pemphigoid. *Immunology and Allergy Clinics of North America*. doi:10.1016/j.iac.2012.04.002
- Schmidt, E., Groves, R. Bullous pemphigoid. In: Griffith, C., Barker, J., Bleiker, T., Chlamers, R., Creamer D. 2016. *Rook's Textbook of Dermatology*. 9th ed. Chichester, West Sussex: John Wiley & Sons Inc. 50.11-20
- Schmidt, E., Zillikens, D., 2013. Pemphigoid diseases. *The Lancet* 381, 320–332. doi:10.1016/S0140-6736(12)61140-4
- Venning, V.A., Taghipour, K., Mohd Mustapa, M.F., Highet, A.S., Kirtschig, G., 2012. British Association of Dermatologists' guidelines for the management of bullous pemphigoid 2012. *British Journal of Dermatology*. doi:10.1111/bjd.12072
- Wojnarowska, F., Kirtschig, G., Highet, a S., Venning, V. a, Khumalo, N.P., 2002. Guidelines for the management of bullous pemphigoid. *The British journal of dermatology* 147, 214–21.
- Zhao, C.Y., Murrell, D.F., 2015. Advances in understanding and managing bullous pemphigoid. *F1000Research*. doi:10.12688/f1000research.6896.1