

# Heat Therapy as an Excellent Adjuvant Treatment for Severe Chromoblastomycosis: A Case Report

Lusiana, Rizky L. Prayogo, Rahadi Rihatmadja, Sandra Widaty, Sri Linuwih Menaldi, Eliza Miranda.

Department of Dermatology and Venereology, Faculty of Medicine Universitas Indonesia / Dr. Cipto Mangunkusumo General Hospital, Jakarta Indonesia.

Keywords: chromoblastomycosis, heat therapy, itraconazole.

Abstract: Chromoblastomycosis is a subcutaneous infection commonly found in tropical and subtropical areas, caused by dark-pigmented fungi (*Dematiaceae*). The disease is most frequently observed in extremities with previous history of trauma and is associated with agricultural occupation. It is characterized by a clinical presentation of verrucous nodule or plaque, muriform bodies on direct smear and histopathological examination and slow growing, black-brown colony on the culture. It has been reported that several treatment options for chromoblastomycosis are studied with varied cure rate, both physical therapy and systemic antifungal drugs. Heat therapy was a method that applies heat to the lesion thereby inhibit the growth of fungi. Here we report a severe chromoblastomycosis case which had combination treatment of heat therapy and itraconazole and showed favourable outcome.

## 1 INTRODUCTION

Chromoblastomycosis (CBM) commonly occur in tropical and subtropical regions, and it is caused by *Dematiaceae* such as *Fonsecaea pedrosoi*, *Phialophora verrucosa* and *Cladophialophora carrionii* as the most common pathogen species. (Hay, 2012, Queiroz, 2017) *Dematiaceae* refers to fungi containing melanin in their cell walls microscopically visible by a gross brown, olivaceous, or black pigmentation. (Queiroz, 2017) Fungi inoculation exist because of direct transcutaneous implantation in the lower extremity as the predilected area, followed by upper extremity and upper part of the trunk with the history of trauma and associated with particular occupation in the farm land or in the agricultural field. (Queiroz, 2015)

The initial lesion may begin with erythematous macular or squamous papule, and then it may gradually extended within months or years and eventually become polymorphic, hyperkeratotic papules-nodules, cauliflower-like or verrucous plaques with atrophic scar in the middle part. (Hay, 2012, Queiroz, 2017, Agarwal, 2017, Purim, 2017) Diagnosis is established based on medical history,

physical examination and identified *Dematiaceae*. The presence of muriform or sclerotic bodies by direct examination with potassium hydroxide (KOH) and histopathological examination and also on the culture we can find slow-growing, black-brown colonies with soft hairy surface.

It has been reported that there are several therapeutic options for CBM, such as physical therapeutic methods (heat therapy, excisional surgery, electrosurgery, CO2 laser, heat therapy, and photodynamic therapy) and systemic antifungal agent. (Queiroz, 2017, Hiruma, 1993-Hira, 2002) According to several open and noncomparative clinical trials, itraconazole is the standard therapy for CBM, and it is also the most common antifungal drug used that can be combined with other modalities. The recovery rate varies, however in the chronic case and severe lesion it is common to get insufficient outcome with high rate of disease recurrence. Heat therapy is a potential therapeutic option for CBM that is easy to use with good response. Several complications that is commonly encountered in CBM are secondary bacterial infection that may cause lymphatic fibrosis and extremity elephantiasis. Chronic diseases may also developed to become squamous cell carcinoma. (Hira, 2002)

## 2 CASE

A 50-year-old male visited the Dermatology and Venerology Outpatient Clinic at the Dr. Cipto Mangunkusumo General Hospital on 7 September 2017 with chief complaint of cauliflower-like masses with black spots that has spread to the right lower extremity since 10 years ago. Initially, the middle finger of the right feet was hurt by knife, and then red spot appear in the dorsal pedis, above the wound surface and extended gradually, become hyperkeratotic papules-nodules, cauliflower-like or verrucous plaques with atrophic scars in the middle part. The lump was itch and painful especially after activities, sometimes bleeding if it is scratched or traumatized. The patient had several medical consultations at the Community Health Centre where he received antihistamine, pain killer, and topical therapy. However, the symptoms did not improved. The patient frequently worked at the farm land, taking care of crops without any foot cover. Previous history of malignancy, lung disease or chronic cough in the patients and family were denied.

On physical examination, the general condition and vital signs were within normal limit. On the right lower extremity and ventral side of the right foot, there were multiple erythematous and skin-colored papules, nodules, vegetative plaques with black spots. There were hypertrophic scars between these lesions (Fig.2a). There was no enlargement in the lymph node. The direct examination with KOH showed some muriform cells or sclerotic bodies.

Histopathological examination revealed hyperplasia pseudoepitheliomatosa appearance, and in the dermis there were lymphocyte cells infiltration, histiocytes, plasma cells and multinucleated and Langhans giant cells. There were muriform cells with thick wall and brown-coloured in the cytoplasm of giant cell (Fig.1a). Tissue culture on Sabouraud's dextrose agar (SDA) medium grown slow-growing, dark-brown colonies, with slightly elevated center (Fig.1b). Microscopic examination with lactophenol cotton blue (LPCB) staining revealed brown conidiophores, ovoid conidia that located at the end or at the side of conidiophores concluded as *Fonsecaea pedrosoi* (Fig.1c).

All of these examination results supported the diagnosis of CBM. Patient was given itraconazole 200 mg daily combined with heat therapy. As the heat therapy, patient used hot water rubber pocket with temperature around 50–60°C for 30-60 seconds, 3 times daily (Fig.1c). Clinical improvement has

been observed within 1 month of therapy. Visually, the swelling became smaller, black granules were disappeared, the pain and itch symptoms were vanished. During 4 months of follow up, most of the swelling was thinner (Fig.2b). Nodular type lesion was faster to become small compared to plaque-shaped lesions and hypertrophic scars. The liver and kidney functions was routinely examined every month.

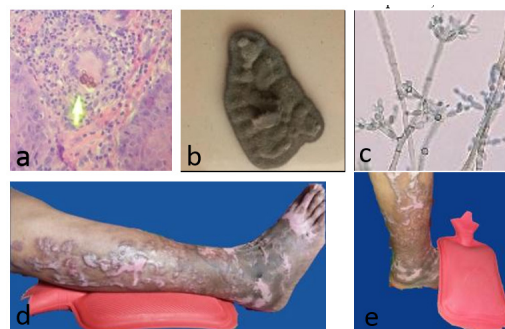


Figure 1. a. Muriform cells, b. Colony of *F. pedrosoi* (macroscopic), c. Slide culture of *F. pedrosoi* (microscopic, LPCB), d-e. Heat therapy procedure.

## 3 DISCUSSION

Chromoblastomycosis is more common in male, with male-to-female ratio of 4:1, and predominantly between 30-50 years of age because risk of trauma was higher in these groups of population. (Santos,2007) Disease transmission was due to inoculation of non-intact skin with fungi *Dematiaceae* from soil or contaminated crops. The patient was a 50-year-old male, works at farm and seldomly use foot protector. Patient had a history of cutting wound on his foot 10 years ago. Several months later there were red spots on the surface above the cut wound. From the medical history, the patient demographic status was consistent with epidemiology characteristic of CBM, such as gender, age, and occupation type. (Santos, 2007) History of trauma surrounding the lesion, history of occupation, and infrequent use of foot protector, were the risk factors that may create a *port d'entrée* for the fungi and eventually resulted in subcutaneous mycosis infection. (Santos, 2007)

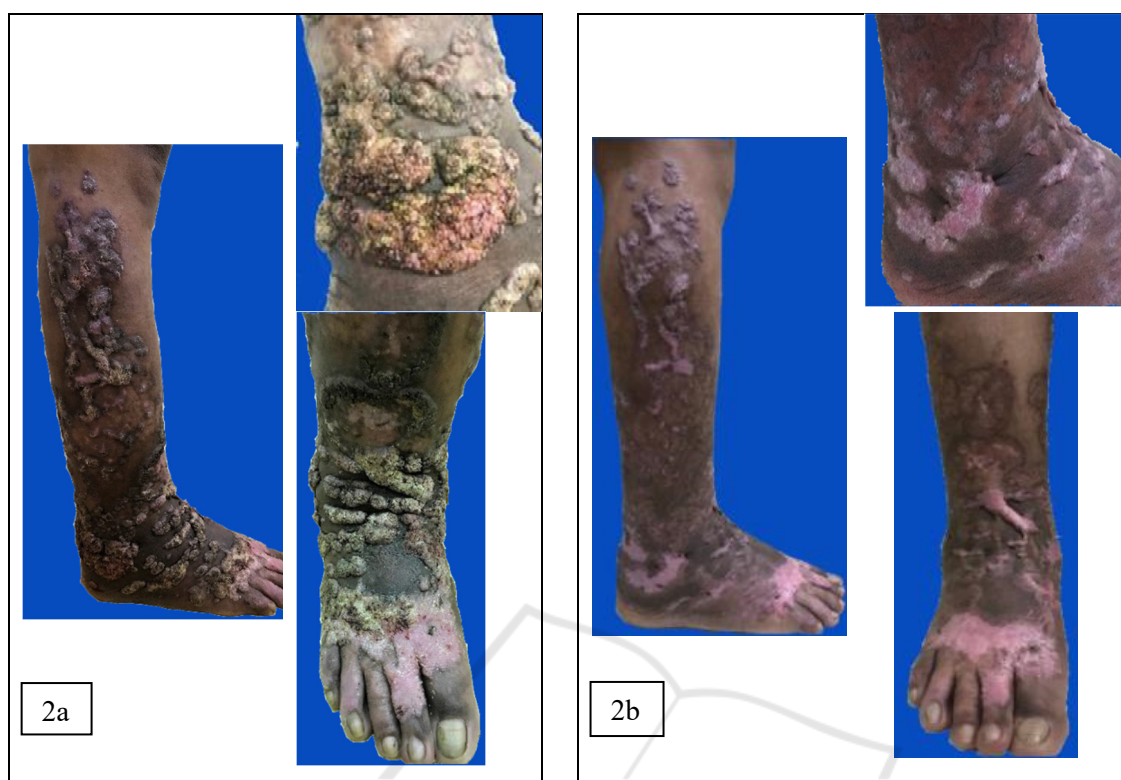

Figure 2. a. Before treatment, cauliflower-like lesions, b. After 4 month combination therapy, the lesions smaller, thinner, black spots disappear.

Diagnostic techniques of CBM are based on physical and direct examination, culture and histopathology. Queiroz, 2009 From direct scrap of KOH and skin biopsy in the lesion surface containing black spots, we could find the disease hallmark of CBM or pathognomonic fungi structure: muriform cell or sclerotic bodies or fumagoid cells or copper pennies. (Queiroz, 2017; Queiroz, 2015; Queiroz, 2009) Muriform cells had thick wall like chestnut, round-shaped, brown color with cross chamber, transversal and longitudinal, and this is as result of fungi adaptation in order to survive in the host tissue. (Queiroz, 2017; Queiroz, 2015) The sensitivity of direct examination with KOH for CBM was 90-100%. (Queiroz, 2017) Therapy may be started upon the demonstration of muriform cells, however, culture identification is important because *Fonsecaea* species may be less sensitive to antifungals. (Queiroz, 2017) From all the signs, symptoms and examinations results in this patient we concluded the diagnosis was CBM and categorized as severe degree based on the lesion size of more than 15 cm<sup>2</sup>.<sup>13</sup>

Therapy of CBM consists of several modalities, such as systemic antifungal medication, physical

therapy, surgical or combination of these modalities. (Queiroz, 2017; Hiruma, 1993) Options and outcome of treatment were dependent by the etiological pathogen, size of lesion, and the degree of the disease, complication, like dermis fibrosis and edema that can reduce the drug concentration in the tissue. The most effective systemic antifungal drugs is itraconazole (200-400 mg/day) or terbinafine (500-1000 mg/day) minimally 6-2 months therapy. In the refractory cases, both drugs could be given simultaneously. *F. pedrosoi* was said to be insensitive to systemic antifungal drugs compared to *C. carrionii* and *P. verrucosa* and there was a report of resistance to itraconazole. (Hira, 2002, Andrade, 2004) In this case, itraconazole was still sensitive with rapid clinical improvement. Heat therapy was a method that applies heat so that the lesion temperature reach 42-45°C. (Queiroz, 2015) The mechanism of action relies on fungal intolerance to high temperature. (Queiroz, 2017) Yanase et al. reported that maximal temperature of *F. pedrosoi* for growth was 39°C. (Yanase, 1978) Heat therapy has particularly been applied in Japan, with several methods. Application of a chemical pocket warmer occluded with a bandage over the lesions on 24 h per

day, or local heat therapy for 2 h perday combined with the administration of posaconazole, or combination of heat therapy for 12 h perday and terbinafin, resulted in an improvement of lesions and negative microscopic examination and culture results within 2-8 months. (Queiroz, 2017; Yanase, 1978)

In this case the combination of itraconazole 200 mg/day with heat therapy, using rubber pocket warmer, about 50-60°C for only 30-60 minutes, showed good response within one month, as it was faster than previous reports. During evaluation after four months of treatment, the response was excellent, the swelling became smaller and thinner, and the surface became smoother. The itch and pain were vanished. Itraconazole is planned to be given for 12 months with monthly follow up.

Treatment of CBM needs to be monitored and evaluated clinically, mycologically, histopathologically every three or four months. (Queiroz, 2017) The disease can be assessed as clinically cured if the lesion resolution was obtained completely, with sclerotic scar without subjective symptoms such as pain or pruritus. (Queiroz, 2017, Hira, 2002) Mycological cure is defined by the negative results of direct microscopic and culture. (Queiroz, 2017) In this case direct examinations with KOH showed negative result during four months therapy. Histopathological cure is achieved if there are no muriform cells, microabscesses and granulomas, and are being replaced by the appearance of chronic inactive inflammation and fibrosis. (Queiroz, 2017) The variable cure rate of CBM is 15%–80% depending on the severity of the disease, and it will increase when two or more modalities were used in combination. (Queiroz, 2015, Agarwal, 2017)

#### 4 CONCLUSION

There is a risk of treatment failure and recurrence in CBM. In a patient with severe and extended lesion, the aim of treatment are to reduce the lesion size and control the state of the disease so that there will be no complication and to improve patient quality of life.<sup>Hira, 2002</sup> Heat therapy is a potential therapeutic option for CBM that is easy to use, affordable prices, and combination with itraconazole showed good clinical response in this case.

#### REFERENCES

- Agarwal, R., Singh, G., Ghosh, A., Verma, K. K., Pandey, M., & Xess, I., 2017. Chromoblastomycosis in India: review of 169 cases. *PLoS neglected tropical diseases*, 11(8), 1-13, e0005534.
- Andrade, T. S., Castro, L. G., Nunes, R. S., Gimenes, V. M., & Cury, A. E., 2004. Susceptibility of sequential *Fonsecaea pedrosoi* isolates from chromoblastomycosis patients to antifungal agents. *Mycoses*, 47(5-6), pp. 216-221.
- Ameen, M., 2009. Chromoblastomycosis: clinical presentation and management. *Clinical and Experimental Dermatology: Clinical dermatology*, 34(8), pp. 849-854.
- Hay R.J., 2012. Deep fungal infections. In: Goldsmith LA, Katz SI, Gilchrist BA, Paller AS, Leffel JD, Wolff K, editor. *Fitzpatrick's dermatology in general medicine*. 8<sup>th</sup> Edition. New York: McGraw-Hill, 2312-2317.
- Hira, K., Yamada, H., Takahashi, Y., & Ogawa, H., 2002. Successful treatment of chromomycosis using carbon dioxide laser associated with topical heat applications. *Journal of the European Academy of Dermatology and Venereology*, 16(3), pp. 273-275.
- Hiruma, M., Kawada, A., Yoshida, M., & Kouya, M., 1993. Hyperthermic treatment of chromomycosis with disposable chemical pocket warmers. *Mycopathologia*, pp. 122(2), 107-114.
- Hu, Y., Huang, X., Lu, S., Hamblin, M. R., Mylonakis, E., Zhang, J., & Xi, L., 2015. Photodynamic therapy combined with terbinafine against chromoblastomycosis and the effect of PDT on *Fonsecaea monophora* in vitro. *Mycopathologia*, 179(1-2), pp. 103-109.
- Purim, K. S. M., Peretti, M. C., Fillus Neto, J., & Olandoski, M., 2017. Chromoblastomycosis: tissue modifications during itraconazole treatment. *Anais Brasileiros de Dermatologia*, 92(4), pp. 478-483.
- Queiroz-Telles, F., Esterre, P., Perez-Blanco, M., Vitale, R. G., Salgado, C. G., & Bonifaz, A., 2009. Chromoblastomycosis: an overview of clinical manifestations, diagnosis and treatment. *Medical mycology*, 47(1), pp. 3-15.
- Queiroz-Telles, F., 2015. Chromoblastomycosis: a neglected tropical disease. *Revista do Instituto de Medicina Tropical de São Paulo*, 57, 46-50.
- Queiroz-Telles, F., de Hoog, S., Santos, D. W. C., Salgado, C. G., Vicente, V. A., Bonifaz, A., ... & Pana, Z. D., 2017. Chromoblastomycosis. *Clinical microbiology reviews*, 30(1), pp. 233-276.
- Santos, A. L., Palmeira, V. F., Rozental, S., Kneipp, L. F., Nimrichter, L., Alviano, D. S., ... & Alviano, C. S., 2007. Biology and pathogenesis of *Fonsecaea pedrosoi*, the major etiologic agent of chromoblastomycosis. *FEMS microbiology reviews*, 31(5), pp. 570-591.
- Shantala, G.B., Rudresh, S.M., Nagarathamma, T., 2011. Chromoblastomycosis: A Case Report. *JCDR*, 5(4), pp. 864-866.

Yanase, K., & Yamada, M., 1978.. Pocket-warmer'therapy of chromomycosis. *Archives of dermatology*, 114(7), pp.1095-1095.

