

# Management for Dengue Hemorrhagic Fever in Pregnancy: A Case Report

Rajuddin<sup>1</sup>, Lutfi Nograho<sup>2</sup>

<sup>1</sup>Division of Reproductive Endocrinology & infertility, Department Obstetric & Gynecology, university of Syiah Kuala, Banda Aceh, Indonesia

<sup>2</sup>Department Obstetric & Gynecology, university of Syiah Kuala, Banda Aceh, Indonesia

**Keywords:** Dengue Hemorrhagic Fever, pregnancy, thrombocytopenia

**Abstract:** Dengue hemorrhagic fever is a common tropical disease in Indonesia. Nowadays, the incidence has been increasing among adults and more cases of dengue fever and dengue hemorrhagic fever in pregnancy are being reported. We managed one case of dengue hemorrhagic fever during pregnancy which developed during antepartum periods. We diagnosed dengue hemorrhagic fever during pregnancy with clinical pictures of fever, hem concentration, thrombocytopenia and serological test. This case was treated conservatively. The patient has recovery and has already discharged. The patient came again after 3 days with chief complaint water broke history previous C section, so we decided to perform emergency C Section. Patient and the baby were in good condition before discharged. Where dengue is endemic, dengue infection should be highly suspected in cases of febrile pregnant women. A knowledge of its diagnosis and management plays a vital role for an obstetrician, particularly regarding to the mode of delivery. Supportive care with analgesics, bed rest, adequate fluid replacement and maintenance of electrolyte balance forms the main stay of treatment. The management of most cases was conservative.

## 1 INTRODUCTION

Dengue fever has become a major health problem especially in tropical countries. Nowadays, the incidence has been increasing among adults and more cases of dengue fever and dengue hemorrhagic fever in pregnancy are being reported. Dengue infection in pregnancy increases the risk of haemorrhage for both the mother and the newborn. Increased incidence of preterm births and fetal deaths has been reported due to dengue infection in pregnancy.(Undurraga,2015) In the literature only about 400 cases of dengue during pregnancy have been reported, mainly describing the maternal and fetal outcomes.(Paixao,2016) Diagnosis of dengue infection affects obstetric management, particularly the mode of delivery due to the potential risk of haemorrhage secondary to thrombocytopenia. A knowledge of its diagnosis and management plays a vital role. We report a case of dengue fever in pregnant woman 36 weeks gestational age with history previous C section.

Dengue, a mosquitos-borne flavivirus infection, is hyperendemic in Indonesia. Dengue hemorrhagic fever is a leading cause of hospitalization of children in Southeast Asia. During the past three decades in Indonesia. A number of patients who have dengue hemorrhagic fever has increased by several years. Hence, one should be aware of an increase in incidence of the infection during pregnancy. We managed one patient who developed dengue infection during third trimester. She was admitted to the Zainoel Abidin general hospital Banda Aceh and serologic test showed primary dengue infection. The effect on pregnancy and management are discussed here.

## 2 CASE REPORT

A 21-year- old, gravida 2 woman who had been a life long citizen Banda aceh was hospitalized in at 36 weeks gestational age with previous c section 1 time. She had undergone high fever for 3 days and epistaxis associated with malaise. She was admitted

9 month of pregnancy, according to last menstrual period correspond due to 36 weeks gestational age (wga). Patient did ANC regularly every month at Obgyn. She went to the Obgyn for ultrasound her pregnancy 4 times. The last ultrasound 2 weeks ago said that the estimation fetal weight about 2000 gram, mother and fetal was in good condition. she complained of high fever with petechiae at both hand and headache that began 1 days prior to admission at the Zainoel Abidin Hospital Banda Aceh. She complained epistaxis before she came to the Hospital. She developed epigastric pain and vomiting. She also has spontaneous bleeding from her nose, headache, tenderness in both leg and epigastric pain, defecation and mixturition within normal limit. She didnt complaint contraction, bloody show and water broke. no have flu symptomp. no history of fluor albus. Active fetal movement.

On examination patient was conscious. She was febrile 39.1 Celsius degrees. Her heart rate was 120/min, blood pressure was 110/70mmhg, respiratory rate was 21 breaths/min. pulse rate was 120/min. Lungs were clear and no cardiac murmurs were noted. She was started Intense fluid resuscitation.( Normal saline) Bolus of 5-10 ml/kg/hour 1-2 hours given followed by 3-5 ml/Kg/Hour as a maintainance. Paracetamol 500 mg and Ranitidine for epigastric pain. she was treated with antipiretic drugs for 2 days.The fundal eight was compatible with 36 weeks gestational age. The fetal hearth rate was reassuring. Petechiae sized 1-2 mm in diameter were found around the arms.

Her hemoglobin was 10.3 g/dl; Hct 32%; TLC 11.000 cells/cumm; platelet count 108,000 cells/cumm; SGOT(315U/L) and SGPT (15U/L); NS1Ag negative and IgG and IgM for dengue were positive. Laboratory findings included the highest level of hemoglobin concentrations of 10.7 g/dl, hematocrit of 34% , and the lowest platelets of 35.000 on the fifth day. other laboratory findings were within normal limit. She was diagnosed as having dengue hemorrhagic fever grade II during pregnancy and treated with intravenous fluid replacement and close monitoring of vital sign and laboratory every 12 hours. After 2 days admission, the epigastric pain dissapeared and the vital signs were within normal limits. On the sixth day, the patient gradually recovered and the hematocrit was 32% with platelet count 45.000. on the ninth day the platelet count 125.000 She was discharged on the tenth day. Serologic study indicated primary Dengue infection. At 37 weeks gestation, she came with water broke. We decided to perform emergency C section because history previous C section. Born a

healthy male baby weighing 2650 grams by C section with an APGAR score at 1 min 9, and 5 min of 10. No abnormality was detected.

### 3 DISCUSSION

Treatment and outcome of dengue in pregnant women are similar to those of nonpregnant women. Misdiagnosis or delayed diagnosis are often because of the overlapping clinical and/or laboratory features. The clinical and laboratory features are similar with other disease that accompanied the pregnancy. For examples HELLP syndrome, pneumonia, pulmonary embolism, various obstetric causes of pervaginal bleeding and other infectious diseases.(Friedman,2016) Adverse pregnancy outcome is still uncertain whether dengue is a significant factor for adverse

Pregnancy outcomes such as preterm birth, low-birth weight and caesarean deliveries. The risk of vertical transmission is well established among women with dengue during the perinatal period. Significant impact of dengue at parturition are severe bleeding may complicate delivery and/or surgical procedures that performed on pregnant patients with dengue during the critical phase, i.e. the period coinciding with marked thrombocytopenia with or without plasma leak. Dengue fever does not warrant termination of pregnancy. There is insufficient data of Probable embryo developmental disorder to mothers who had Dengue infection in first trimester.(Ribeiro,2015)

If delivery is inevitable, bleeding should be anticipated and closely monitored. Blood and blood products should be cross-matched and saved in preparation for delivery. Trauma or injury should be kept to the minimum if possible. It is essential to check for complete removal of the placenta after delivery. Transfusion of platelet concentrates should be initiated during or at delivery but not too far ahead of delivery, as the platelet count is sustained by platelet transfusion for only a few hours during the critical phase. Fresh whole blood/fresh packed red cells transfusion should be administered as soon as possible if significant bleeding occurs. If blood loss can be quantified, it should be replaced immediately. Do not wait for blood loss to exceed 500 ml before replacement, as in postpartum haemorrhage. Do not wait for the haematocrit to decrease to low levels. Oxytocin infusion should be

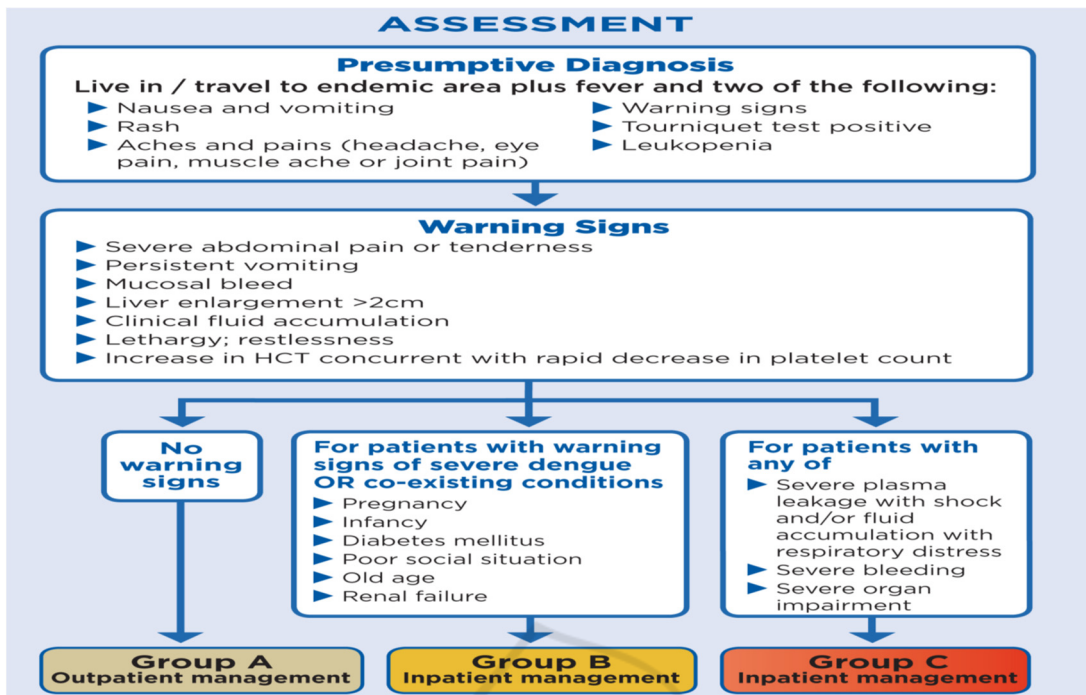


Figure 1: Dengue case management modified from WHO guideline for Dengue Hemorrhagic fever

given for uterine contraction after delivery to prevent postpartum haemorrhage. Misoprostol may be given for post partum hemorrhage Prophylaxis/treatment. Intramuscular injections are to be avoided.(Chitra,2015)

### 2.3 Management of dengue hemorrhagic fever in pregnancy

All pregnant patients with suspected DHF are advised for close monitoring.

DF without warning signs: (Group A).(Friedman,2016)

Monitor:

- 4 hourly Temperature charting , pulse, Blood Pressure and Pulse pressure.
- Ensure urine output at least 4-6 hours.
- ( minimum 100 cc every 4 hours)
- Capillary refill Time
- Intake Out put record.
- Labs : Daily Complete Blood Count , other investigations if necessary.

Treatment:

- Paracetamol 500-650 every 6 hours. Warn the patient that fever may not settle with this dose but NOT to exceed 4 grams paracetamol in 24 hours. Nor to take

other NSAID like ibuprofen and diclofenac Sodium.

- Oral Intake encouraged such as Oral rehydration solution, coconut water, Kanji, juice all are encouraged apart from routine food. Aim of at least 2.5 litres. If Nausea/Vomiting of pregnancy restrict oral intake give IV fluid (NS) 100 cc/ hour. (Friedman,2016)

Doctor on duty should be notified if : less Urine output, vomiting, lethargy, narrowing of pulse pressure, delayed capillary refill.>2 seconds Warning symptoms and signs for capillary leak are to be looked for vigilantly specially so when fever starts subsiding. As warning signs hallmarks capillary leak and she can progress to severe Dengue .These are patients for IV fluid therapy.(Chitra,2015)

- Abdominal pain and tenderness
- Persistent vomiting
- Lethargy, restlessness
- Liver enlargement >2 cm , Capillary refill getting delayed. UOP less
- Mucosal Bleed : epistaxis, gum bleed petechiae.
- Rise in HCT (20% of baseline)
- DHF with Warning sign (Group B).(Friedman 2016)

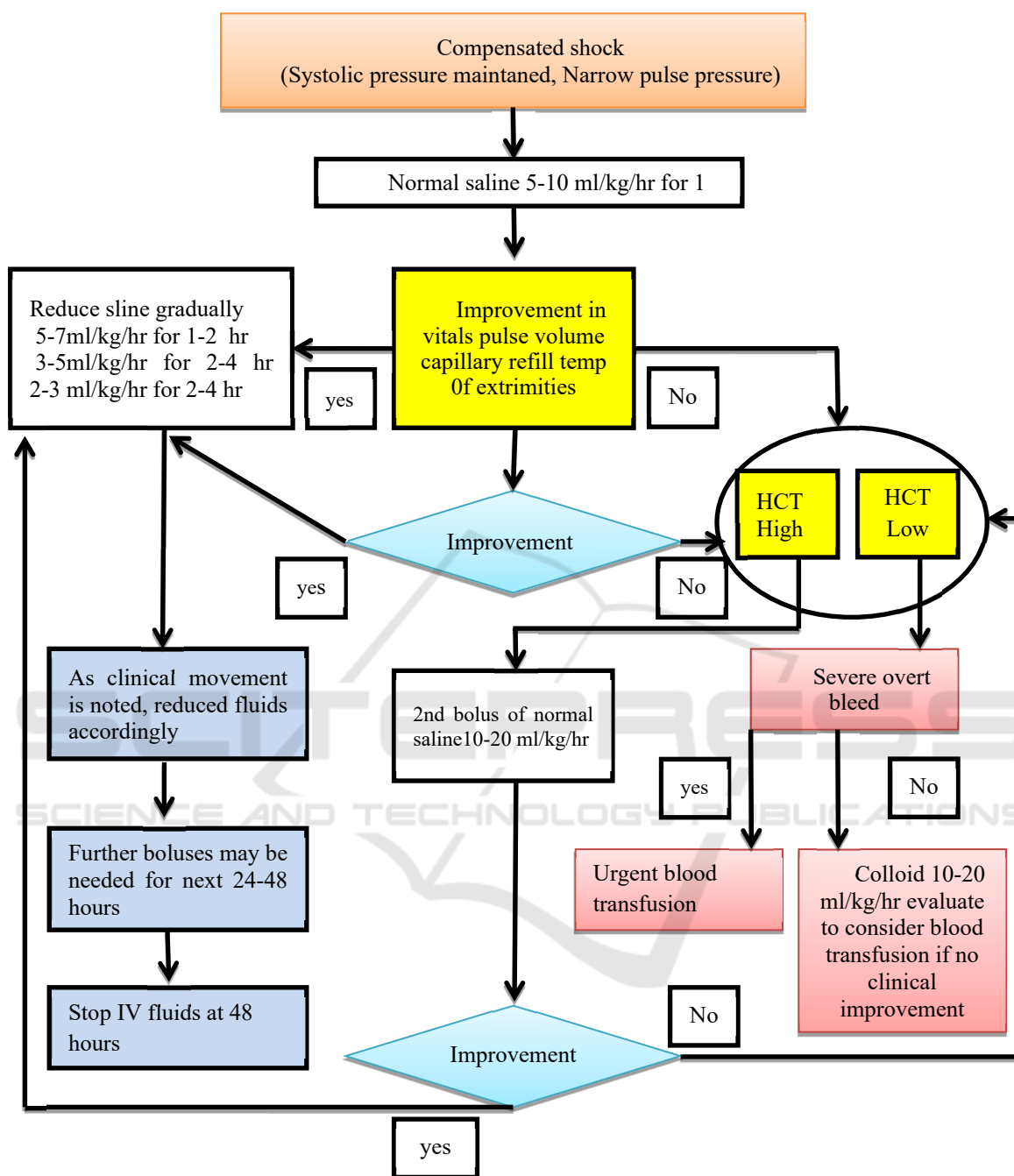


Figure 2: Treatment Algorithm for Dengue Hemorrhagic Fever in pregnancy modified from WHO Guideline

Check vitals sign every hours. Catheterize to know precise urine output hourly ( Aim 0.5ml/kg/hour). Intense fluid resuscitation.( Normal saline) Bolus of 5-10 ml/kg/hour 1- 2 hours given followed by 3-5ml/Kg/Hour as a maintenance. This is monitored by urine output and Pulse pressure.

Avoid induction of labour/ planned surgery in this phase.(Ribeiro,2015)

DHF with shock on admission (Group C), these patients need institutional management in ICCU setup. Timely fluid management with appearance of any warning symptom practically prevents further

complication before transferring this patient.(Chitra,2015)

- Draw blood for CBC, to know HCT.
- Also for group cross match, SGOT,SGPT, Electrolytes, sugar etc.
- Fluids Bolus given as (NS) 10cc /kg over 15 minutes before transfer
- And second bolus as 10ml/kg for next 1 hour during transfer.
- Hand over all reports , fluid bolus details for reference for further treatment.

Prophylactic platelet transfusion is NOT recommended unless delivery is inevitable ( in coming 6 hours) platelet count > 50000/CC, and 75000/cc for operative delivery. Clinically stable Dengue with Low or very Low platelet count in critical/recovery phase didn't need platelet transfusion. Platelet transfusion may be given in presence of Overt bleeding with Low platelet counts. Platelet transfusion was generally avoided unless there was significant bleeding or platelet counts less than 20.000.(Schexneider,2015)

Operative delivery for obstetric indications only. Avoid Planned induction and surgery. The presence of wounds or trauma during the critical phase of dengue with marked thrombocytopenia, and plasma leak creates a substantial risk of severe haemorrhage. Delivery should take place in a hospital where blood/blood components and a team of skilled obstetricians and a neonatologist are available.(Kariyawasam,2016)

#### 4 CONCLUSIONS

Dengue fever in pregnancy most often is treated conservatively. Platelet count may fall rapidly but no active intervention required unless patient is in labour or has bleeding disorder. Dengue infection in pregnancy may have resulted in maternal morbidity and mortality. Gestational age of occurrence of dengue fever seems to have a role early or late in pregnancy had a poor prognosis. Treatment for dengue infection in pregnancy is supportive and need attention to fluid balance, maintaining normothermia, platelet count and monitoring for shock and consideration of delivery management. Severe thrombocytopenia requiring initial resuscitation with blood and blood products prior to and during delivery. Platelet transfusion may be given in presence of Overt bleeding with Low platelet counts. Platelet transfusion was generally

avoided unless there was significant bleeding or platelet counts less than 20.000. A thorough investigation should be conducted so as to confirm the infection and prevent further maternal and fetal complications.

#### REFERENCES

- Guzman, G., J. Gubler, A. Izquierdo, E. Martinez, and S. B. Halstead., 2016. *Dengue infection*. Nature Reviews Disease Primers., 2: 55-60
- Guzman,G.J., E. Harris.,2015. *Dengue*. The Lancet. 385 (96): 453–465.
- Unduraga, E. A., M. Betancourt-Cravioto, J. Ramos-Castañeda et al., 2015. *Economic and Disease Burden of Dengue in Mexico*. PLOS Neglected Tropical Diseases. 9 (3): 347-354.
- WHO., 2014 *Dengue Haemorrhagic Fever: Diagnosis, Treatment, Prevention and Control*. World Health Organization, Geneva, Switzerland.
- Paixao, E. S., G. Teixeira, M. D. C. N. Costa, and L. C. Rodrigues.,2016. *Dengue during pregnancy and adverse fetal outcomes: A systematic review and meta-analysis*. The Lancet Infectious Diseases. 16(7): 857–865.
- Friedman, E. E., F. Dallah, E. W. Harville et al. 2016. *Symptomatic dengue infection during pregnancy and infant outcomes: a retrospective cohort study*. PLOS Neglected Tropical Diseases. 8(10); 58-64
- Ribeiro, C. F., V. G. Lopes, P. Brasil et al., 2015. *Dengue during pregnancy: association with low birth weight and prematurity*. 58(6): 64-72
- Chitra, T. V., Chitra and S. Panicker.,2015. *Maternal and fetal outcome of dengue fever in pregnancy*. Journal of Vector Borne Diseases. 48(4): 210–213.
- Schexneider, K. I., E. A. Reedy., 2015. *Thrombocytopenia in dengue fever*. Current Hematology Reports. (2): 145–148
- Kariyawasam, S., H. Senanayake.,2016. *Dengue infections during pregnancy: case series from a tertiary care hospital in India*. The Journal of Infection in Developing Countries. 4( 11): 767–775.