

Application of Multichannel Electrical Stimulation of the Neck Nervous Structures in Patients with Depressive Disorders: An fMRI Case Study

Vladimir Kublanov¹, Timur Petrenko¹ and Aleksandr Efimtcev²

¹Ural Federal University, Mira 19, Yekaterinburg, Russian Federation

²The Almazov National Medical Research Centre, St. Petersburg, Russian Federation

Keywords: Neuro-electrostimulation, Neuroimaging, functional MRI, Depression Disorder.

Abstract: The article presents the pilot functional neuroimaging study results of the treatment process by means neuro-electrostimulator SYMPATHOCOR-01 in patients with depressive disorder. The study involved three patients. The changes in the brain's default mode network (DMN) as a result of neuro-electrostimulation course are demonstrated. Along with clinical improvement (HDRS-21 and BDI-II scales), changes in DMN's performance from neuroimaging data are shown. An increase in the medial prefrontal cortex and cingulate gyrus functional connection activity with various parts of the brain was noted. These changes indicate the activation of neuroplasticity processes and restoring the work of DMN in patients with depression.

1 INTRODUCTION

The rapid spread of depressive disorder among the working-age population of developed countries determines the relevance of the search for effective treatment and rehabilitation approaches of this disease. It is known that depressive disorder occurs at any age, acutely limiting a person's adaptation to changing environment. In the European Union the depression came in first place among causes of the able-bodied life years loss. The direct and indirect economic losses associated with this disorder exceed 300 billion euros per year. (Research Institute of Scientific and Technological Information, 2014)

Modern neurophysiological studies have discovered the most important role of impaired neurotrophic regulation processes in the pathogenesis of depressive disorder (Licznernski and Duman, 2013). There was a marked decrease frontal cortex activity - responsible for analytical functions and decision making (Bremner et al., 2002; Cotter et al., 2001); hippocampus and amygdala - participating in the processes of learning and memory, emotional response (Rajkowska et al., 2001; Sheline, 2003); autonomic centers of the brain stem - regulating the work of the internal organs, circadian processes and neurogenesis

activity (Khalsa SBS et al., 2000).

Neuroplasticity is a combination of multi-level processes of continuous morphofunctional reorganization of the brain, thus providing adaptation to changing external and internal conditions. The most studied of the processes of neuroplasticity are the processes of neurotrophic regulation. The actions of neurotrophic factors are explained through the activation of genetically programmed regulation mechanisms impacting to nervous tissue. In the case of depression, we are talking about damage of the basic neuroplasticity processes, as evidenced by numerous studies (Doan et al., 2015; Kraus et al., 2017; Liu et al., 2017).

Today to get a new knowledge about brain potential possibilities and search the effective methods of stimulating neuroplasticity processes a priority task of the basic sciences in all developed countries.

A modern medical approach to the treatment of depressive disorder is aimed at regulating synaptic transmission processes due to indirect increase activity of certain neurotransmitters (such as serotonin, norepinephrine and dopamine). As clinical practice shows, this approach has poor effectiveness. Only one third of patients with depressive disorder respond to antidepressant therapy (Culpepper et al., 2015).

Innovative approaches involved neuroplasticity processes is more effective, because of affecting to pathological mechanisms accompanying depression. Modulation of neurotrophic regulation makes it possible to influence to electrochemical transmission of nerve impulses and activate the process of neuroprotection (Malykhin and Coupland, 2015).

Emergence of the modern neurovisualization methods opens the possibilities in the neuroplasticity investigation. Functional magnetic resonance imaging (fMRI), which is an intravital non-invasive dynamic investigation of active brain structures during their functioning.

The purpose of the study is to identify brain functional changes in treatment depressive disorder patients by the SYMPATHOCOR-01 device by means of fMRI. Results, presented in the study are an extended version of previously published case study (Kublanov et al., 2018).

The SYMPATHOCOR-01 neuro-electrostimulation device is essentially the technology of multi-channel neuro-electrostimulation by means of a spatially distributed physical field (Kublanov et al., 2012).

The device is included in the register of medical equipment products of the Russian Federation (registration certificate № FCR 2007/00757) and has the Certificate of correspondence to the requirements of the regulations GOST R 50444-92.

The spatially-distributed field of the current pulses is formed between two multi-element electrodes of the device. Each multi-element electrode comprises a cluster of thirteen partial current-conducting elements. The multi-element electrodes are arranged on the neck into left and right sides. In the working state, one element of one multi-element electrode performs the role of the anode. Elements on the other side become the cathodes.

A feature of the extension in current work is the implementation of the multifactorial nature of neuro-electrostimulation due to the realization of the possibility to change the field structure, the stimulation target and to choose bio-tropic parameters of current pulses, adequate to the anatomical location of the stimulation targets.

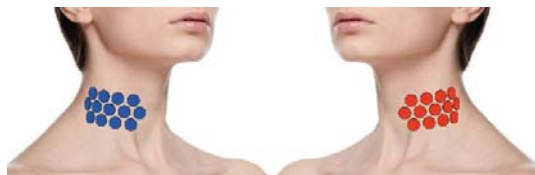

Figure 1: Scheme of the partial current-conducting elements of the multi-element electrodes location.

Placing the multi-element electrodes on the subject neck, the central elements of multi-element electrodes have to be located in projections of the neck ganglia of the sympathetic nervous system targets (Fig. 1).

Note the following basic bio-tropic characteristics of the field: the current partial pulses duration τ is from 15 to 60 usec. The frequency f of pulses group is from 5 to 150 Hz. The cathode elements are switched accordingly to each given rule (for example, a pseudo-random with the clockwise or counterclockwise direction of switching, and so on). The used anode is set depending on the stimulation target. In this work upper and middle neck ganglia of the sympathetic nervous system are used as the target. The duration of the anode connection varies from 30 seconds to several minutes and is controlled by the physician. The current pulses amplitude can be up to 15 mA.

The treatment application of the neuro-electrostimulation device is implemented as the DCASNS technique (Dynamic Correction of the Sympathetic Nervous System Activity) (Kublanov et al., 2014). The DCASNS technique provides correction of autonomic balance, which is characterized by the ratio between the sympathetic and parasympathetic departments of the autonomic nervous system (ANS) (Kublanov et al., 2017).

2 MATERIAL AND METHODS

Depending on pathogenesis of the peripheral or central dysfunctions of the ANS, the dynamic correction of the activity sympathetic nervous system (DCASNS) algorithm has two different branches. Decision of which branch should be executed is based on nature of the ANS dysfunction. The bio-tropic parameters of the implemented current pulse field (the field structure, pulses amplitude, frequency, and duration) are calculated from the analysis of the heart rhythm variability. In particular, in the case of the abnormal hyperactivity of sympathetic innervation, it is necessary to block or suppress the activity of the sympathetic nervous system. In contrast, sympathetic innervation should be increased, if the hyperactivity of the parasympathetic innervation is observed. In case of central dysfunctions, the bio-tropic parameters of the stimulation field are calculated, based on analysis of the main activity rhythms of the cerebral cortex and its deviation from the norm.

In clinic practice, the 'SYMPATHOCOR-01' device and DCASNS algorithm were efficiently

applied for treatment of various diseases including organic and/or functional disorders of the CNS and/or the ANS: consequences of brain trauma or stroke, epilepsy, chronic headache, somatoform disorders, anxiety and depressive spectrum disorders, attention- deficit hyperactivity disorder, disorders involving cognitive impairments (Kublanov et al., 2017).

In the December of 2017, at the State Scientific-Research Institute of Physiology & Basic Medicine (SSRI PBM), the pilot study of the hemodynamic reactions, caused by the neuronal activity of the brain, by means of the rfMRI, was conducted.

The study was conducted with the approval of the Research Institute of Biomedical Ethics SSRI PBM. Protocol of the local ethical committee # 13 dated 16.11.2017.

Three patients diagnosed with ICD F33 have participated in this pilot study. The patients have signed the informative participation consent. The study was carried out on the MR system GE Discovery MR750W, 3.0 Tesla, in accordance with the following protocols:

T1 SPGR 3D reconstruction, up to 256 cross-sections, voxel size 1 mm³; mandatory capturing the whole head surface, including nose and ears;

fMRI in the resting state mode (33 cross-sections, thickness up to 4,5 mm)

T2-WI, FLAIR (weighted images for exclusion of the chronic gliosis sources). The stimuli were sent by means of the Nordic NeuroLab BrainEx.

For registration to standard space a T1 high-resolution 3D MPRAGE (magnetization prepared rapid gradient echo) was performed. with the following scan parameters: repetition time (TR)=2.5 s, echo time (TE)=3.52 ms, 190 sagittal slices with no gap, field-of-view (FoV)=230 mm, flip angle (FA)=8°, in-plane resolution=1.2×1.2 mm², slice thickness=1.2 mm. During RS-fMRI acquisition, using gradient echo T2* weighted EPI, participant was instructed to keep the eyes closed and not to think about anything. The imaging parameters were: 100 volumes, TR=3000 ms, TE=52 ms, FA=90°, 33 interleaved slices, slice thickness=4,5 mm, imaging matrix 64×64 and FoV=220 mm. The study timeline is presented in the table 1.

Table 1: Study timeline.

I phase	II phase
-T1-sag	-T1-sag
-RS	-RS
-Visual Nordic	-Visual Nordic
-DTI	-DTI
-MRA	-MRA

Here: T1-sag – weighted image in the sagittal projection; RS - resting state functional MRI (BOLD signal); MRA - MR-angiography, a medical test that helps physicians diagnose and treat medical conditions and diseases of the blood vessels.

The first phase was conducted before treatment for the baseline state evaluation. The second phase was conducted 5 days after 5 procedures of the DCASNS, and in order to evaluate long term reaction of the CNS.

The biotropic field features of the SYMPATHOCOR-01 were set in accordance with the DCASNS technique. There were one 15-minutes procedure every day.

Our research team has experience in processing and analyzing neuroimaging data in similar clinical tasks (Efimtsev et al., 2014; Shelepin et al., 2018; Sokolov et al., 2017; Trufanov et al., 2016).

Statistical analysis of data and evaluation of the results of neuroimaging studies, as well as individually or in group totally (resting state fMRI data), were performed using CONN v.18 software package (Functional connectivity Toolbox), designed to determine the relationships between different brain regions, including dynamic mode, connectivity mapping, determining the structure of various resting state networks and functional networks of the brain.

This tool enables voxel correlation analysis (communication between voxel groups) by plotting the time dependencies between the BOLD signal from a given voxel / group of voxels and each voxel in the scan area. Many types of data are used for processing. We used the analysis based on the regions of interest measures (ROI-to-ROI), because it corresponds to our main goal, is suitable for performing individual analysis and provides a visual graphical (and quantitative) representation in the form of brain functional connectivity maps. For a ROI-based analysis, Medial Prefrontal Cortex was chosen as a seed ROI, as it is considered a part of default mode network (DMN).

Evaluation of clinical status of patient was performed twice - before and after the course of neuroelectrostimulation. Clinical assessment was supplemented by symptom scores on psychometric scales: Beck Depression Inventory (BDI-II) (Beck et al., 1996), Hamilton Depression Rating Scale (HDRS-21) (Hamilton, 1960). During the study, patients did not take any additional antidepressant therapy.

3 RESULTS

The data of clinical dynamics, assessment of psychometric scales and fMRI analysis of research are given. At the end of the section the group analysis data is represented.

Abbreviations: PFC - positive functional connectivity; NFC - negative functional connectivity; MPFC — Medial Prefrontal Cortex; PCC - posterior cingulum; BA – Brodmann area

Patient No. 794., Male, 28 years. Diagnosis: recurrent depressive disorder of the current severe episode (F33.2).

Table 2: Psychometric scales dynamics.

BDI-II		HDRS-21	
Before	After	Before	After
51	32	28	6

Before treatment, there were obvious signs of depression, visible in appearance, even by a non-expert. Noticeable inhibition and unproductive thinking and motor activity. The content of thinking is the experience of failures and mistakes of life, excessive concern for health. Serious sleep disorders.

After treatment – all indicators are in the normal range, except the motivation to work.

In patient 794 in 2 phase, the following changes were identified in comparison to 1 phase (before stimulation):

- “normalization” of the DMN, which was expressed in the presence of all areas of activation, usually detected in healthy subjects.
- recovery of positive FCs of the medial prefrontal cortex with the left lower temporal gyrus, anterior cingulum, left angular gyrus, right postcentral gyrus, precuneus, right middle frontal gyrus, right upper frontal gyrus, the left caudate;
- the change in the localization of negative FC of the medial prefrontal cortex: FC with the lateral occipital cortex bilaterally, the left temporal lobe, the left medial frontal gyrus appeared, FCs with opercular cortex, thalamus, insula disappeared (Fig. 2).

Before Treatment: symptoms of depression are determined by appearance. Expresses ideas of guilt and meaninglessness of his life. Severe insomnia. Feelings of powerlessness and lethargy. Pronounced fluctuations in mood throughout the day and alarming concerns about the state of their health.

After Treatment: depressive symptoms are detected only with the active questioning of the patient.

Sleeping has improved significantly, and anxiety has almost disappeared. Activity and cheerfulness appeared.

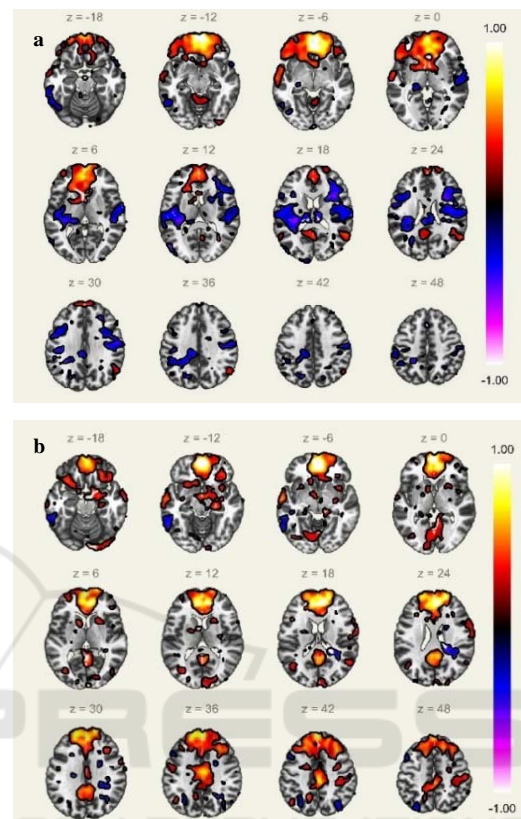


Figure 2: Patient 794. Resting state fMRI maps – before treatment (a), after treatment (b) show the changes in the default brain network ($p < 0.001$).

Patient No. 889. Woman, 53 years. Diagnosis: recurrent depressive disorder current episode average (F33.1).

Table 3: Psychometric scales dynamics.

BDI-II		HDRS-21	
Before	After	Before	After
38	27	17	5

In patient 889, before stimulation, the functional connectivity of the MPFC was distributed as follows:

- expressed negative FCs predominantly in the left hemisphere with temporal lobes (middle and superior temporal gyri), right thalamus, hippocampus and putamen, left pre- and postcentral gyri, parietal region (BA5, BA7);
- positive FCs with anterior and orbital parts of the frontal lobes, and with the precentral cortex

(BA4), and the visual cortex

After stimulation, the DMN was represented as “normal”:

- negative FSs symmetrically with the frontal cortex (BA6, BA8, BA9), with the parietal region (BA5, BA7) became significantly weaker, but the lateralization of the remaining FCs was still present (in the left hemisphere)
- appeared (recovered) positive FCs with posterior cingulum, angular gyri, right middle and superior temporal gyrus, hippocampus. At the same time, the positive FCs with basal ganglia, putamen, caudate, right insula, paracingular was preserved. In this way, this patient had a rather expressed dynamics, both according to HDRS-21, and according to rfMRI, which demonstrated almost complete “stabilization” of DMN (Fig. 3).

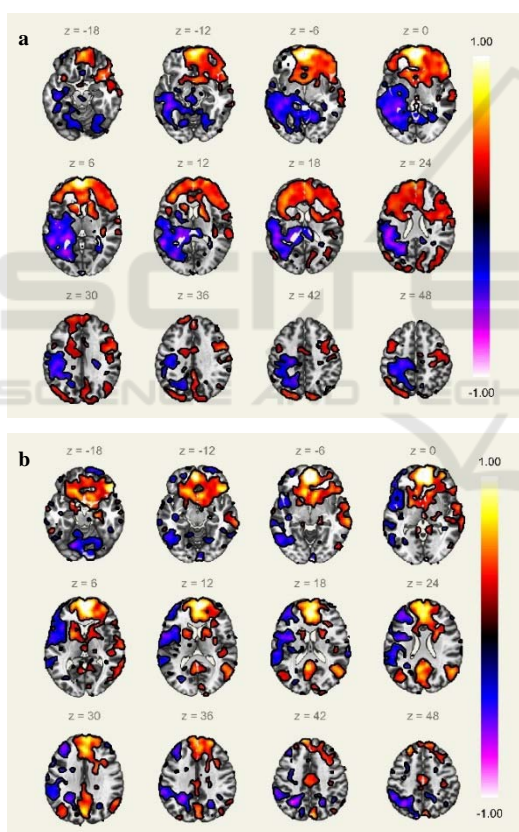


Figure 3: Patient 889. Statistical maps of post-processing of resting state fMRI: before treatment (a), after treatment (b) show the changes of functional connectivity in default mode network ($p < 0.001$).

Patient No. 865., Female, 54 years. Diagnosis: recurrent depressive disorder current episode average (F33.1).

Table 4: Psychometric scales dynamics.

BDI-II		HDRS-21	
Before	After	Before	After
13	11	17	6

Before treatment: pronounced signs of depression during patient questioning. Severe insomnia in all stages of sleep. Loss of interest in the environment. Inhibition of thought and speech. Alarming concerns about your health.

After treatment: no depressive statements; no insomnia; active talks about inner state; there was a feeling of unreality and automaticity of what is happening (depersonalization).

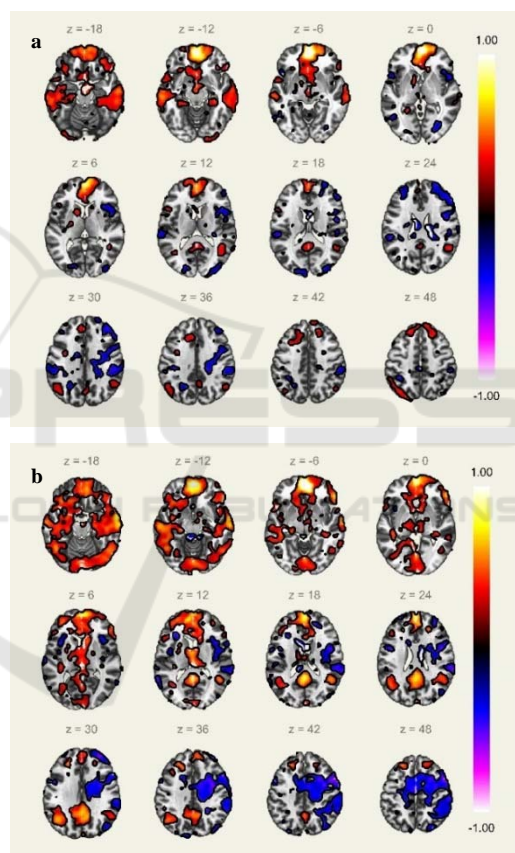


Figure 4: Patient 865. Statistical maps of resting state fMRI - before treatment (a), after treatment (b) show the changes of functional connectivity in default mode network ($p < 0.001$).

In patient 865, who had a less expressed degree of depression (on the Hamilton scale) and, accordingly, insignificant dynamics after treatment, the appearance of positive FCs with bilateral angular gyri, lateral occipital cortex, bilateral fusiform gyri. Negative FCs remained unchanged at all time points. It should be noted that in this subject the cerebral

papillary at one time point was characterized by functional connections that are close to “normal”, although they were less expressed (Fig. 4).

The results of the comparative analysis (phase 2 > phase 1) in Fig. 5 and tab. 5.

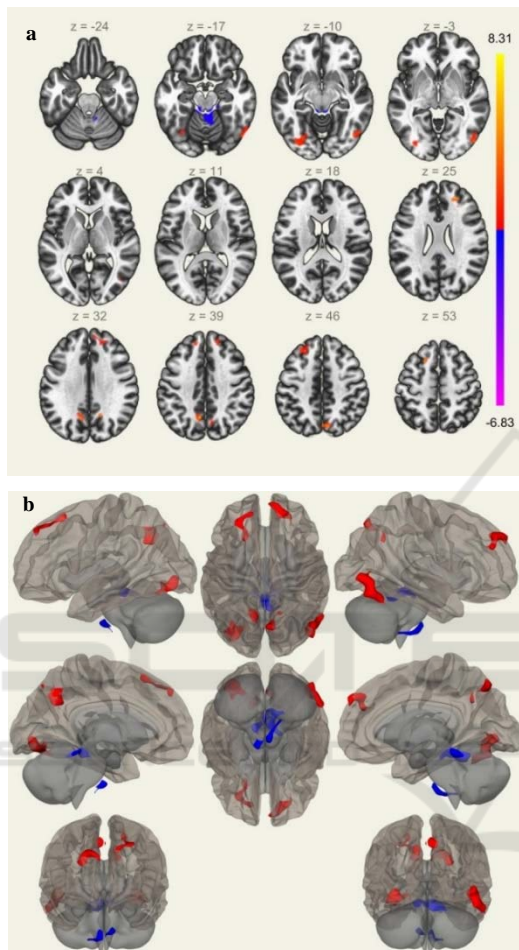


Figure 5: Comparative group analysis of the functional connectivity of the brain in subjects before the beginning of rehabilitation and after completing the full course of rehabilitation: 2D statistical map (a), 3D statistical map reconstruction (b) ($p < 0.005$).

Table 5: Resting-State fMRI in the group of patients with depressive disorder in comparison with the data after the course of rehabilitation.

Brain region	T	Voxels	Volume	MNI coordinats
Cerebelum 3 (left hemisphere)	-3.62	59	472	(-9; -37; -19)
Cerebelum 3 (right hemisphere)	-2.95	95	760	(12; -35; -19)
Occipital Fusiform Gyrus Left (Precuneous)	2.53	210	1680	(-27; -77; -14)
Precuneous Cortex	2.38	202	1616	(1; -59; 38)

Lateral Occipital Cortex, inferior division Right	2.27	358	2864	(46; -74; -02)
Vermis 3	-2.17	99	792	(1; -40; -11)

4 DISCUSSION

Summarizing the results obtained, it can be said that the dynamics of changes using rfMRI confirms the clinical dynamics, which is even more expressed than more serious initial condition of the patient. In many publications, the authors talk about changes in the stability and variability of the functioning of the DMN, especially its main parts - the MPFC and PCC, which are involved in realization of deep cognitive functions, a complex analysis of both the surrounding and inner human world.

The correlation of the functional connections of these areas among themselves, as well as with other parts of the brain and the severity of depression, was determined. Considering the brain DMN, in all the patients in the Stimulation group it was “normalized” - due to the restoration of the main positive FCs between MPFC, PCC and angular gyri. In all patients in the “Stimulation” group, before treatment, the fMRI-pattern was characterized by complete “instability” of DMN, with a predominance of negative FCs. Some scientists talk about changes in local connectivity in the frontal lobes. Such a phenomenon may occur, for example, in patient 889, in whom positive FCs were strongly expressed in these areas. These activation patterns can be considered as a mechanism of hyper-compensation in response to an episode of depressive disorder, as well as FCs with the parietal region - as a predictor of episode relapse.

Some patients showed changes in the FCs of the hippocampus and insular cortex with MPFC. According to many authors, the function of these areas, incl. as part of the limbic system, changes in depressive disorders, demonstrating reduced connectivity. It is known that these brain structures contribute in the formation of the emotional background, which can thus explain their main role in the mechanisms of development of a deep depressive disorder, including the early stages. Patient 865 had a feeling of unreality and automaticity of what is happening (depersonalization) probably reflected by more expressed negative FCs between MPFC and insula on the right, as well as increased local positive FCs between MPFC and ventrolateral prefrontal cortex (right and left). The involvement of these brain areas

in the depressive process is reflected in some research.

5 CONCLUSIONS

In the course of 5 procedures of neuro-electrostimulation using SIMPATHOCOR, the restoration of MPFC and PCC connectivity was noted in these three patients, which brought their DMN to the “normal state”. However, the conclusion must be coordinated with the initial state of the DMN, which has variable individual characteristics. This fact must be considered in further similar studies in large groups.

The important point noted in the course of the study is the fact that the “normalization” of the DMN appeared the stronger, the more severe the symptoms were observed in the patient. This indicates the use of the most powerful mechanisms of neuroplasticity, which are being “turned on” after neuro-electrostimulation.

ACKNOWLEDGEMENTS

This data acquisition within the study (Chapter 3) was supported by the Act 211 of the Government of the Russian Federation (contract no. 02.A03.21.0006). Data processing (Chapter 4) was funded by RFBR (project no. 18-29-02052).

Authors are grateful to all staff of SIRBPM who participated in the organization of research. Special thanks to Maria Rezakova for her help in obtaining fMRI signals.

REFERENCES

- Beck, A.T., Steer, R.A., Ball, R., Ranieri, W., 1996. Comparison of Beck Depression Inventories -IA and -II in psychiatric outpatients. *J Pers Assess* 67, 588–597.
- Bremner, J.D., Vythilingam, M., Vermetten, E., Nazeer, A., Adil, J., Khan, S., Staib, L.H., Charney, D.S., 2002. Reduced volume of orbitofrontal cortex in major depression. *Biol. Psychiatry* 51, 273–279.
- Cotter, D., Mackay, D., Landau, S., Kerwin, R., Everall, I., 2001. Reduced glial cell density and neuronal size in the anterior cingulate cortex in major depressive disorder. *Arch. Gen. Psychiatry* 58, 545–553.
- Culpepper, L., Muskin, P.R., Stahl, S.M., 2015. Major Depressive Disorder: Understanding the Significance of Residual Symptoms and Balancing Efficacy with Tolerability. *Am. J. Med.* 128, S1–S15.
- Doan, L., Manders, T., Wang, J., 2015. Neuroplasticity underlying the comorbidity of pain and depression. *Neural Plast.* 2015, 504691.
- Kublanov, V., Dolganov, A., Aftanas, L., Petrenko, T., Danilenko, K., Maria, R., Efimtcev, A., Babich, M., Sokolov, A., 2018. Investigation of the Neuro-electrostimulation Mechanisms by Means of the Functional MRI: Case Study. In: *Proceedings of the 11th International Joint Conference on Biomedical Engineering Systems and Technologies - Volume 3: NENT (BIOSTEC 2018). Presented at the Special Session on Neuro-electrostimulation in Neurorehabilitation Tasks*, pp. 319–324.
- Efimtsev, A., Fokin, V., Sokolov, A., Voronkov, L., Trufanov, A., 2014. Morphometric Basis of Depression in Parkinson’s Disease and the Possibility of Its Prediction. In: Ślęzak, D., Tan, A.-H., Peters, J.F., Schwabe, L. (Eds.), *Brain Informatics and Health, Lecture Notes in Computer Science. Springer International Publishing*, pp. 357–365.
- Hamilton, M., 1960. A rating scale for depression. *J. Neurol. Neurosurg. Psychiatry* 23, 56–62.
- Khalsa SBS, null, Jewett, M.E., Duffy, J.F., Czeisler, C.A., 2000. The timing of the human circadian clock is accurately represented by the core body temperature rhythm following phase shifts to a three-cycle light stimulus near the critical zone. *J. Biol. Rhythms* 15, 524–530.
- Kraus, C., Castrén, E., Kasper, S., Lanzenberger, R., 2017. Serotonin and neuroplasticity - Links between molecular, functional and structural pathophysiology in depression. *Neurosci Biobehav Rev* 77, 317–326.
- Kublanov, V., Babich, M., Dolganov, A., 2017. Principles of Organization and Control of the New Implementation of the “SYMPATHOCOR-01” Neuro-electrostimulation Device. Presented at the Special Session on Neuro-electrostimulation in Neurorehabilitation Tasks, pp. 276–282.
- Kublanov, V., Shmirev, V., Shershever, A., Kazakov, Y., Porshnev, S., Vasilev, A., 2014. About innovative possibilities of the device SIMPATOCOR in management of functional disorders of vegetative and central nervous system in neurology. *Kremljovskaya Medicina* 1, 60–64.
- Kublanov, V.S., Porshnev, S.V., Danilova, I.G., Goette, I.F., Levashkina, A.O., Syskov, A.M., 2012. Experimental modeling of the effects of autonomic regulation in the correction of immobilization stress rats. *Biomedical Radioelectronics* 56–67.
- Licznerski, P., Duman, R.S., 2013. Remodeling of axospinous synapses in the pathophysiology and treatment of depression. *Neuroscience* 251, 33–50.
- Liu, W., Ge, T., Leng, Y., Pan, Z., Fan, J., Yang, W., Cui, R., 2017. The Role of Neural Plasticity in Depression: From Hippocampus to Prefrontal Cortex. *Neural Plasticity* 2017, 1–11.
- Malykhin, N.V., Coupland, N.J., 2015. Hippocampal neuroplasticity in major depressive disorder. *Neuroscience* 309, 200–213.

- Rajkowska, G., Halaris, A., Selemon, L.D., 2001. Reductions in neuronal and glial density characterize the dorsolateral prefrontal cortex in bipolar disorder. *Biol. Psychiatry* 49, 741–752.
- Research Institute of Scientific and Technological Information, 2014. Public analytical report on the direction of “*Neurotechnology*.”
- Shelepin, K.Y., Trufanov, G.E., Fokin, V.A., Vasil’ev, P.P., Sokolov, A.V., 2018. Digital visualization of the activity of neural networks of the human brain before, during, and after insight when images are being recognized. *J. Opt. Technol., JOT* 85, 468–475.
- Sheline, Y.I., 2003. Neuroimaging studies of mood disorder effects on the brain. *Biol. Psychiatry* 54, 338–352.
- Sokolov, A.V., Vorobyev, S.V., Efimtcev, A.Y., Dekan, V.S., Trufanov, G.E., Lobzin, V.Y., Fokin, V.A., 2017. fMRI and Voxel-based Morphometry in Detection of Early Stages of Alzheimer’s Disease: In: *Proceedings of the 10th International Joint Conference on Biomedical Engineering Systems and Technologies. Presented at the 4th International Conference on Bioimaging, SCITEPRESS - Science and Technology Publications*, Porto, Portugal, pp. 67–71.
- Trufanov, A.G., Litvinenko, I.V., Odinak, M.M., Voronkov, L.V., Khaimov, D.A., Efimzev, A.Y., Fokin, V.A., 2016. Cortical cerebral atrophy in patients with Parkinson’s disease: New opportunities for in vivo diagnostics. *Hum Physiol* 42, 905–909.

