

# Physical Medicine and Rehabilitation Role in Pre-Operative Management of Patient with Giant Bullae of Right Lung with Scoliosis and a History of Systemic Lupus Erythematosus: A Case Report

Andreas Ricky<sup>1</sup>, Tresia Fransiska U Tambunan<sup>2</sup>

<sup>1</sup>*Department of Physical Medicine and Rehabilitation, Dr. Cipto Mangunkusumo Hospital, University of Indonesia, Jakarta, Indonesia*

<sup>2</sup>*Cardiorespiratory Division, Department of Physical Medicine and Rehabilitation, Dr. Cipto Mangunkusumo Hospital, University of Indonesia, Jakarta, Indonesia*

**Keywords:** Giant Bullae, Systemic Lupus Erythematosus, Pre-operative Management, Pulmonary Rehabilitation Program.

**Abstract:** Giant bullae refers to the enlargement of one or more bullae occupying more than one-third of the hemithorax. It creates larger and less efficient lung sacs that can't properly manage the normal gas exchange during breathing. Systemic Lupus Erythematosus (SLE) is a chronic inflammatory disease with pulmonary manifestations is giant bullae due to excessive surface tension secondary to surfactant failure. Female patient with history of SLE presenting with shortness of breath during moderate-intensity activities. CT Scan showed giant emphysematous bullae in her right hemithorax. Patient had double curve scoliosis which may affect her chest expansion. Evaluation of respiratory functions showed lung restrictive disease and its predictive post-operative value of forced expiratory volume in one second (ppoFEV1) below 30%. During 8 weeks pulmonary rehabilitation program patient's clinical state is improved and associated with increase in forced expiratory volume in one second (FEV1). Home based aerobic exercise consisted of walk 15 minutes/day, 5 days a week. Due to her limited chest expansion, active breathing exercise and scoliosis program exercise administered in the rehabilitation program. This case report elaborates on the effect of the pre-operative pulmonary rehabilitation program in improving respiratory function and its readiness to undergo surgical treatment.

## 1 INTRODUCTION

Giant bullae, referred to as vanishing lung syndrome as a clinical syndrome, characterised by large bullae that occupying at least one-third of one or both hemithoraces (Huang et al., 2014; Garg et al., 2016).

Emphysema in giant bullae causes a loss of elasticity in the walls of the small air sacs in the lung. Eventually, the walls of the sacs stretch and break, which creates larger, less efficient sacs that can't properly handle the normal exchange of oxygen and carbon dioxide that occurs during breathing. Difficulty in fully exhaling usually leads to the capture of air in the lungs, known as hyperinflation (Giant Bullae. Health Encyclopedi, 2019).

SLE is a chronic inflammatory disease of autoimmune origin that can affect virtually every organsystem of the human body (Lopez Velazquez and Highland, 2018). Pulmonary manifestations of SLE include airway disease, pleuritis (with or without effusion), inflammatory and fibrotic forms of interstitial lung disease (ILD), alveolar hemorrhage, acute lupus pneumonitis (ALP), pulmonary hypertension, giant bullae and thromboembolic disease.

Pulmonary manifestations in systemic lupus erythematosus (SLE) are relatively common but giant bullae is the least common clinical manifestation. Fewer than 100 cases have been reported in the medical literature. Although giant bullae can be asymptomatic, patients are usually experience dyspnea caused by underlying

emphysema. Surgical resection is treatment of choice for patients with giant bullae. The goals are to improve the quality of life for those in whom medical treatment has failed and to resolve complications while preserving lung function. Surgical resection is considered only after an assessment of exercise capacity, pulmonary-function testing, and smoking cessation. Determination of the preoperative bulla volume allows the prediction of the expected increase of postoperative FEV1 (Giant Bullae. Health Encyclopedia, 2019).

Based on the recommendations of the Enhanced Recovery After Surgery (ERAS®) and the European Society of Thoracic Surgeons (ESTS) pulmonary rehabilitation and prehabilitation is strongly recommended and so is perioperative nutrition screening and oral nutritional supplements (Batchelor, 2019). We report a case of a patient with giant bullae, scoliosis, and SLE whose pulmonary function improved significantly after following prehabilitation program.

## 2 CASE PRESENTATION

A 43-year-old woman, a nonsmoker presented in August 2019 with shortness of breath during moderate-intensity activities. Patient has a history of giant bullae of her right lung which was diagnosed on January 2019. Patient started to experience shortness of breath while conducting regular activities which gradually worsened. She would feel shortness of breath after climbing one flight of stairs although she could still walk 500 meters without the symptom. Patient also began experiencing fever. The fever was accompanied with frequent vomiting and non-productive cough. A chest radiograph (Fig. 1) revealed increased lucency in the upper half of the right hemithorax suspected as several loculated pleural effusions. This was followed by a chest computed tomography (CT) scan that revealed a giant bullae occupying her right lung accompanied by pleural effusion on both bases of her lungs. (Fig.2).

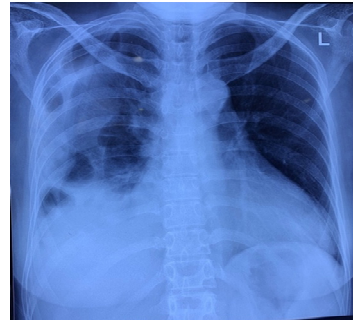


Figure 1: Chest radiograph suspect loculated pleural effusion in right upper zone, with increased interstitial markings in lower zone.

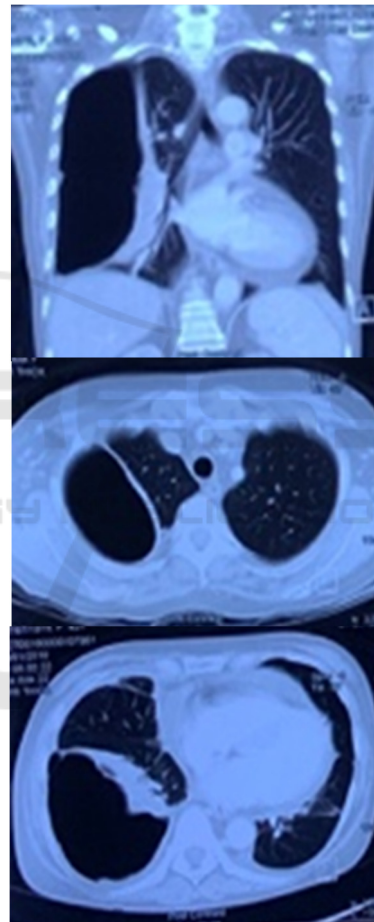


Figure 2: CT chest – Giant bullae in right lung, with loculated pleural effusion and calcified pleura at basal right lung.

Patient has a history of SLE that was first diagnosed in the year 2000. Afterwards put her in routine medication (methylprednisolone, myfortic). In 2006 she began experiencing back pain that gradually worsened over the time and diagnosed with osteoporosis. Patient also took kolkatriol and CaCO<sub>3</sub> once a day. The patient denied any history of tuberculosis, diabetes mellitus type 2, stroke, and cardiovascular illnesses.

The patients social history; The patient is a housewife. She was a never smoker, but had exposure to environmental tobacco smoke. She did have any exposure to biological or industrial dusts. There was no family history of respiratory illnesses.

On examination, she had a heart rate of 99 beats per minute, and a blood pressure of 140/94. The respiratory rate was 21 breaths per minute, with an oxygen saturation of 97% on ambient air. She was of small build with BMI 16,4 (underweight). Respiratory examination revealed a vesicular breath sounds, with reduced sound on the right hemithorax, no rhonchi, no wheezing. Hyperresonance was found in lateral right hemithorax during chest percussion. She had thoracoabdominal breathing pattern, with contraction of inspiratory accessory muscle, slightly delayed chest expansion on right hemithorax, and inadequate effort to cough. Chest expansions were decreased, with a difference between inspiration and expiration of 5.

In postural examination, patient left shoulder is slightly higher than the right, vertebral alignment S-shaped with convexities on left mid-thoracic region and right thoracolumbar region, pelvic obliquity positive with right side higher than the left, very slightly observable hump on right mid-thoracic region of the vertebrae. Spasm paravertebral muscles was found on the concave side. Schober test is 15 + 4 cm, and with Adams test showed a functional scoliosis with hump (height 1 cm) on right side of mid-thoracic region (T6) 6 cm from midline.

Patient was consulted for a rehabilitation program as the patient is waiting for surgery. Pre-operative management aimed to increase cardiorespiratory endurance, strengthening of diaphragm muscle, increase chest wall mobility, reduce muscle imbalance due to scoliosis, energy conservation, and improve nutritional status.

Table 1: Baseline lung function and capacity test.

Chest Expansion	5cm – 5 cm – 6cm
PFR	2.70 L/s
FVC	1.09 L (32% pred)
FEV1	1.00 L (36% pred)
FEV1/FVC	91.74%

6MWT	Mileage: 418 meter (predicted mileage 514.2 meter) = 81.29% Vo2Max: 16.8 METS: 4.80
Chest Expansion	5cm – 5 cm – 6cm

Table 2: Lung Function and capacity test after rehabilitation program.

	4 weeks	8 weeks
Chest Expansion	5cm – 5 cm – 8cm	5cm – 5 cm – 8cm
PFR	3.31 L/s	3.74 L/s
FVC	1.9 L (66% pred)	2.59 L (86.9% pred)
FEV1	1.71 L (69.5% pred)	2.20 L (87% pred)
FEV1/FVC	90%	84.94%
6MWT	Mileage: 409 meter (predicted mileage 518,6 meter) = 78.86% Vo2Max: 15.4 METS: 4.4	Mileage: 465 meter (predicted mileage 517 meter) = 89.2% Vo2Max: 18.4 METS: 5.20

### 3 DISCUSSION

Giant bullae is a disorder characterized by bullae occupying more than a third of the hemithorax, and mostly affects men who are smokers (Kiang, Tan and Li, 2015) In our case, although she never smoked a day in her life, the patient was exposed to cigarette smoke since childhood as her late father was a heavy smoker. In addition, nowadays she lives by a garbage disposal site that burns garbage on a daily basis. Thus, it may not be unreasonable to assume that different triggers incite the same cascade of subcellular inflammatory mediators that cause the destruction of alveolar walls and resulting in permanent and abnormal enlargement of distal airspaces. Interestingly, GB in our patient may have associations with medical conditions (and systemic lupus erythematosus), (Kiang, Tan and Li, 2015)

Enlarging bullae cause symptoms by interfering with respiratory mechanics and gas exchange. As they grow larger, they compress on normal lung parenchyma, reduce lung compliance, and increase work of breathing. As dead space fraction increases with bullae formation, gas exchange is also impaired. This symptom similar in our setting that showed

dyspnea was the main problem, and pulmonary functional study showed restrictive lung disease.

Patient with single giant bulla with underlying normal lung is the “ideal candidates” and stand the best chance of success of surgery. Success is defined as both a lessening of the pressure and other symptoms, and the recovery or restoration of lung function.(Giant Bullae. Health Encyclopedia, 2019) It is still uncertain whether the patient in this case falls in this category. Even with a single giant bulla and remaining lungs mostly in normal condition, the CT result showed a fibrosis in segment 9 of left lung accompanied by pleural effusion. In addition the single giant bulla was formed by combination of multiple giant bulla existed in the right lung with the size of approximately 11.4 x 6.7 x 17.6 cm<sup>3</sup>.

Before planned surgical treatment of lung cancer, the patient's respiratory system function should be evaluated. According to the current guidelines (fig 3), the assessment should start with measurements of FEV1 (forced expiratory volume in 1 second) and DLco (carbon monoxide lung diffusion capacity). Pneumonectomy is possible when FEV1 and DLco are > 80% of the predicted value (p.v.). If either of these parameters is < 80%, an exercise test with VO2 max (oxygen consumption during maximal exercise) measurement should be performed. When VO2 max is < 35 % p.v. or < 10 ml/kg/min, resection is associated with high risk. If VO2 max is in the range of 35-75% p.v. or 10-20 ml/kg/min, the postoperative values of FEV1 and DLco (ppoFEV1, ppoDLco) should be determined. The exercise test with VO2 max measurement may be replaced with other tests such as the shuttle walk test and the stair climbing test. The distance covered during the shuttle walk test should be > 400 m. Patients considered for lobectomy should be able to climb 3 flights of stairs (12 m) and for pneumonectomy 5 flights of stairs (22 m).(Trzaska-Sobczak, M Skoczyński and Pierzchała, 2014)

In this patient the ppoFEV1 was 15 pv and ppoVO2 max was 6.73 ml/kg/min which means surgical treatment was not advised and other therapy was recommended. In 21 studies (including 5 RCTs) focusing on pre- rather than postoperative rehabilitation, the intervention was delivered mainly in the outpatient setting or in a training facility. Prescribed exercises included aerobic training (lower and/or upper limbs), with the addition of strength training in some studies. Respiratory exercises were also included in the majority of studies. The addition of other elements, such as relaxation techniques and educational sessions, were inconsistent. The median duration was 4 weeks (range 1–10 weeks) with a frequency of 5 sessions per week (range 2–14 weeks) of moderate to high intensity, generally tailored to the patient's tolerance.(Batchelor, 2019)

This patient receives pre-operative pulmonary rehabilitation program in outpatient setting which includes: (1) aerobic exercise 5 times a week, (2) respiratory exercises, and (3) exercise program for scoliosis. Aerobic exercise prescribed for moderate intensity although in reality the patient was allowed to do them as tolerated. Based on her 6-minute-walking-test result which was 418 meters in 6 minutes (VO2 max 16.8, METs: 4.80), we decided to prescribe her aerobic exercise starting from 50% of the maximum walking distance from her 6MWT, thus ideally prescribing the patient with 30 minutes-walk (with the same pace as when she walked the 6MWT) for 3 days a week. However, as the patient has had a history of SLE with multiple musculoskeletal manifestation in addition to her sedentary lifestyle, we made the decision to prescribe her aerobic exercise that started low and progress slowly starting with walking for 15 minutes, 5 days a week, instead.

As for her respiratory exercise, the patient receives a set of exercise that consisted of diaphragmatic breathing, deep breathing, chest expansion, and pursed lip breathing. Aside from relaxation effect the exercise may give to the patient each one was prescribed for different reasons. As the right hemithorax could not expand symmetrically with the left one, thoracic expansion could be assisted by excursion of the diaphragm and flexing and abducting the upper extremities. If the patient were to follow through with surgery later on, the patient would be prepared with diaphragm and intercostal muscles that has good strength and flexibility. She would also benefit from the relaxation breathing when experiencing post-surgical pain. While pursed lip breathing helps in airway clearance as the patient has limited

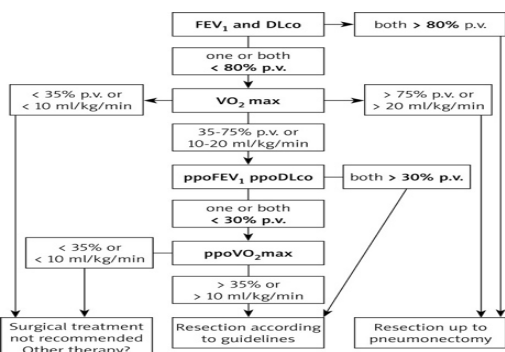


Figure 3: Algorithm for assessing respiratory system function in lung cancer surgery candidates.

inspiratory capacity. In addition, patient was also prescribed 2 session of chest physical therapy aiming to educate her chest mobility exercise. Moreover, a TheraBand strengthening exercise is also planned to strengthen her pectoralis mayor and core muscles that may help with overall recovery.

Scoliosis exercise programs were aimed to correct the muscle imbalance. It consist of (1) strengthening weakened muscles on the convex side, (2) stretching of muscle spasm on concave side with 6 seconds hold, 10 repetitions, 3-5 times/day. ESPEN guidelines recommend delaying surgery to allow for preoperative enteral nutrition in patients with at least one of the following criteria: weight loss >10–15% within 6 months, body mass index (BMI) <18.5 kg/m<sup>2</sup> and serum albumin <30 g/l (with no evidence of hepatic or renal dysfunction). Current general recommendations suggest administration of 5–7 days of oral supplements before surgery in patients at risk of malnutrition.(Batchelor, 2019)

In this case the patient's BMI falls less than 18.5 kg/m<sup>2</sup>, and there hasn't been any lab work up to rule out hepatic nor renal dysfunction considering patient's history of SLE. Patient is planned to be consulted to nutritionist regarding her perioperative nutrition preparation. 4 weeks after home-based program the chest expansion is increase in lower segment. And also increasing in pulmonary function test, ppoFEV1 29 pv, and ppoV02max 6.16 ml/kg.min. After 8 weeks of program FEV1 is increased to 2.20 L (87% pred), so does the ppoFEV1 (36 pv) and ppoVo2max (7.37 ml/kg.min) (table 2). Although patient still was not advised to undergo surgical treatment, better pulmonary function already help patient to do her daily activity. Patient right now can climb 2 flights of stairs without feeling any shortness of breath, and can do housework without any symptoms.

#### 4 CONCLUSIONS

Pulmonary rehabilitation can be given to patient with giant bullae in pre-operative setting. This will lead to better cardiorespiratory endurance, respiratory function, and better endurance to do her daily activity. Pre-operative pulmonary rehabilitation program should be given to the giant bullae patient to increase her readiness to undergo surgical treatment.

#### REFERENCES

- Batchelor, T., 2019 Guidelines for enhanced recovery after lung surgery: recommendations of the Enhanced Recovery After Surgery (ERAS®) Society and the European Society of Thoracic Surgeons (ESTS), *Eur J Cardiothorac Surg*, 55(1), pp. 91–115. doi: <https://doi.org/10.1093/ejcts/ezy301>.
- Garg, I. et al., 2016. Giant Bulla or Tension Pneumothorax: Diagnostic Dilemma in Emergency. *Chest*, 150(4), p. 929A. doi: 10.1016/j.chest.2016.08.1029.
- Giant Bullae. *Health Encyclopedia*, 2019. University of Rochester. Available at: <https://www.urmc.rochester.edu/encyclopedia/content.aspx?contenttypeid=22&contentid=giantbullae>. Accessed: 19 August 2019.
- Huang, W. et al., 2014. Surgery for giant emphysematous bullae: case report and a short literature review, *J Thorac Dis*, 6(Mvv), pp. 104–107. doi: 10.3978/j.issn.2072-1439.2014.04.39.
- Kiang, C., Tan, R. and Li, Y., 2015. Respiratory Medicine Case Reports A breath from Houdini e A case of giant bullous emphysema, *Respir Med Case Rep*, 14, pp. 30–33. doi: 10.1016/j.rmcr.2014.12.003.
- Lopez Velazquez, M. and Highland, K., 2018. Pulmonary manifestations of systemic lupus erythematosus and Sjögren's syndrome. *Curr Opin Rheumatol*. doi: 10.1097/bor.0000000000000531.
- Trzaska-Sobczak, M Skoczyński, S. and Pierzchała, W., 2014. Pulmonary function tests in the preoperative evaluation of lung cancer surgery candidates. A Review of Guidelines. *Kardiochir Torako-chirurgia Pol*, 11(3), pp. 278–82. doi:10.5114/kitp.2014.45677.