

Helminthiasis and Aspergillosis Suspect Examination in Pigeon

Albiruni Haryo and Rifqi Rahman

Laboratory Pathology Anatomy, Faculty of Veterinary Medicine, Brawijaya University

Keywords: Pigeon, Examination, Helminthiasis, Aspergillosis

Abstract: Pigeons are commonly maintained using a simple cage system, this system also easier to transmit disease such as helminthiasis and aspergillosis to infect pigeons. The air of this study was to know and diagnose changes in macroscopic and microscopic with histopathology method in pigeons. The organs examined are proventriculus, intestine, liver, and skin. Macroscopic changes were seen in liver change color into brownish-yellow on right lobes of the liver, hiperemi proventriculus, hemorrhage, and swelling intestine, baldness, and crust in the upper neck skin. Microscopic changes seen in hepar are white blood cell infiltration in triad portal, congesti and ulcer mucosa gland proventriculus, intestine shown epithelial erosion, rupture villi, hemorrhage and hyperplasia of cell goblet and skin shown black colored infiltration in dermis allegedly infected by Aspergillosis sp. From examination and observation, it can be concluded that macroscopic and microscopic changes lead to the helminthiasis and suspected Aspergillosis sp.

1 INTRODUCTION

Pigeons are animals that are maintained extensively with pure cage carrying management in purposes to simplify preservation and inexpensive, but this system aids the transmission of diseases such as helminthiasis and aspergillosis more quickly. The common helminthiasis hitting the pigeons are *Ascaridia Columbae*, *Capillaria* sp, and *Tetramers* sp (Alkharigy et al., 2018). A contaminated feed with worm eggs or through ectoparasites such as fleas can transmit the helminthiasis. In addition to helminthiasis, some diseases such as Aspergillosis are also easily transmitted to pigeon populations, especially if the conditions are humid. Aspergillosis is caused by *Aspergillus* sp, whose transmitted through spores can be inhaled through breathing, digestion, or sticking to the skin and infecting the dove. Helminthiasis and Aspergillosis may cause economic losses due to adult-stage worms living in the digestive tract, causing blockages and interfering with the absorption of nutrients from its pigeons. This study aims to identify helminthiasis and Aspergillosis based on visible macroscopic and microscopic alteration. Macroscopic observation in the neck skins that facing a loss of fur and blackened. Microscopic results indicate aspergillosis infection in the skin. Fungi Aspergillosis sp leads to Aspergillosis. The acute Aspergillosis infiltrates the

dermis and tissue beneath, which could cause necrosis in the infected area (Bernadeschi et al., 2015).

2 MATERIALS AND METHODS

2.1 Instrument and Materials

The applied animal is a pigeon with an age of around four months. The method used to observe macroscopic alteration is the Necropsy method. For histopathological observation, the utilized method is the Histotechnique by doing network isolation and followed by staining the preparations using Hematoxylin-eosin staining, which is conduct at the Anatomy Pathology Laboratory and Histology Laboratory, Faculty of Veterinary Medicine, Brawijaya University

2.2 Animal Preparation

The animal (pigeon), which is four months old approximately, is euthanized by embolism through magnum foramen. The 3 cc syringe loaded with air and injected it to the animal's brain through the foramen magnum.

2.3 Necropsy Implementation

Must ensure the total death from the animal (pigeon) before doing a necropsy. Necropsies stages were performed such cleansing into the incised area by rinsing using the water flow afterward, the fixation and incision were made to see organ abnormalities. The standard necropsy procedure was carried out according to Majo and Dolz (2011). The purpose of a necropsy is carried out to assist overall the examination of organ abnormalities, for macroscopic abnormalities examination, and also sampling for the histopathological preparations.

2.4 Histopathology Preparation

Hematoxylin Eosin staining prep will be using the samples from selected organs that assumed having abnormalities in the pigeons, which are liver, intestine, skin, and proventriculus (Janqueira, 2007).

3 RESULTS AND DISCUSSION

The results of the liver macroscopic examination showed a color change into yellow in the right lobe (Figure 1.) Microscopic examination showed the inflammatory cell infiltrate in the portal triad (Figure 2.) According to Lope et al. (2017), the liver has a complex hemodynamic groove. Blood from the spleen, pancreas, and gastrointestinal flows into the liver through the portal vein along with the hepatic arteries. The inflammation of inflammatory cells is an excessive accumulation of cells in the tissues or blood vessels. Portal triads consist of venules portal, arterioles portal, and bile ducts. Blood flow from the portal vein is blood flow that comes from the intestine, spleen, and rectum so that it contains numerous antigens residual of the intestinal bacteria such as lipopolysaccharide endotoxins (LPS) and leukocytes when there is inflammation due to the infection process in these organs (Bogdanos. et al. 2013).

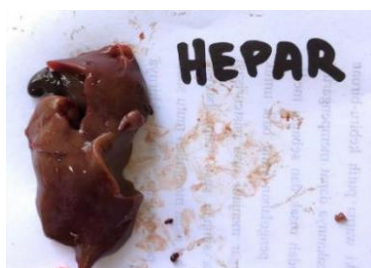

Figure 1. Pigeon's liver that appears turned into yellow in the right lobe on the macroscopic examination (blue arrow).

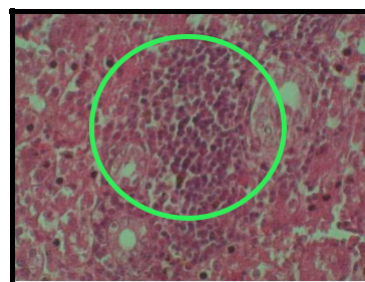


Figure 2. Histopathology of pigeon's liver tissue by Hematoxylin Eosin staining (400x). Annotation : A. Infiltration of inflammatory cells near the central vein (black arrow). Inflammation of inflammatory cells in the triad's portal (inside the green ring).

Macroscopic observations of proventricular organs show hyperemia. The proventriculus is seemed to have a dark red color (Figure 3). The proventricular disorder is an anomaly occurring in specific cases such as Newcastle disease. Pathognomonic lesions of ND disease characterized by the presence of petechiae and hemorrhage in the mucosa proventriculus (Nakamura et al. 2010).

There was no hemorrhage, and petechiae founded in the mucosa in the pigeon's case, but it has hyperemia. Microscopic results showed congestion, mucous gland ulceration, and ruptured proventricular gland (Figure 4). Congestion is a vascular size enlarged. Congestion generally occurs when there was an expansion in tissue activity, increased acid levels, CO₂, also an infection or tissue damage. It is due to vasodilation, and increased blood flows into the area. Increased blood flows to the gastrointestinal commonly occur during the metabolic process. Erosion is a superficial damaged on the surface of the tissue that could be occurred by inflammation, trauma, or parasites that break the extent of the mucosa and does not reach the muscular mucosa. Ulcers are local lesions on the skin or mucosal layer that show damaged superficial epithelium and also in deeper tissues. The histology shows superficial damages that indicate the occurrence of mucosal gland erosions, and the damage also exists unto the (mucosal gland). The proventriculus histopathology shows that the damage has spread into the proventricular glands (Figure 4).

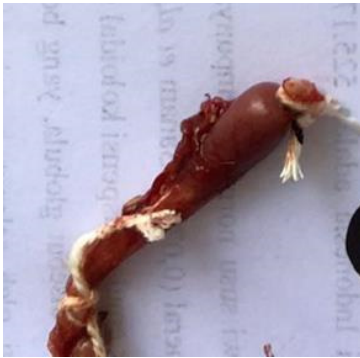

Figure 3. Proventricular hyperemia in pigeons becomes dark red

The results of macroscopic observation of intestine organs show obstruction with hyperemia. Nematode worms which generate the obstruction are visible after cross-section. Microscopic observations revealed epithelial erosion, villi rupture, goblet cell hyperplasia, and hemorrhage (Figure 5).

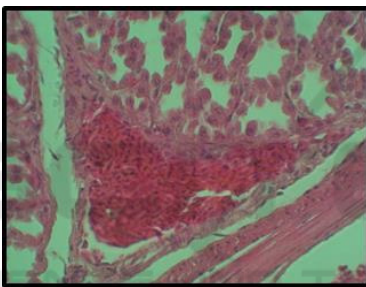


Figure 4. Histopathology of proventriculus tissue with Hematoxylin Eosin staining (400x) Annotation: Congestion in proventricular tissue and erosion, ulcer mucosal gland proventriculus

Helminthiasis damages can create epithelial erosion and villous rupture. The advances in structure cells to goblet cell hyperplasia are the body's defense attempts to react to the antigen or epithelial damage. Healthy goblet cells are present in intestine cells as cells that secrete *mucin*, which serves to cover and protect the intestinal mucosa. Damage to the intestinal epithelium causes more goblet cells to produce mucin as a response to epithelium damages (Djojodibroto, 2007).

Hemorrhage is an escape of blood from ruptured blood vessels, and the bleeding can occur inside or outside of the body. Increased blood pressure, blood vessel infection, and inflammatory blood vessel walls can provoke hemorrhage (Mohan, 2010). Nematodes are one of the causes of bleeding in the intestinal mucosa because it can damage the epithelium and intestine blood vessels. Common

nematodes in pigeon intestines are *Ascaridia columbae*, *Capillaria sp.*, and *Tetramers sp.* (Alkharigy *et al.*, 2018).

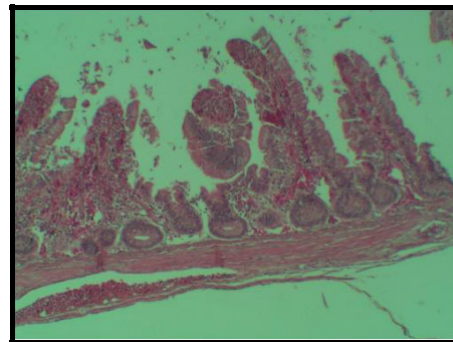


Figure 5. Histopathology of intestine tissue with Hematoxylin Eosin staining (100x) Annotations: Ruptured villi (black arrow). Goblet cell hyperplasia of villi intestine and hemorrhage in the intestine villi.

4 CONCLUSIONS

Pigeon necropsy based on macroscopic and microscopic changes leads to the assumption of helminthiasis with types of nematodes and Aspergillosis. Helminthiasis, especially nematode intestinal, can cause changes both macroscopically and microscopically in the liver and intestine, and Aspergillosis can cause changes both macroscopic and microscopic to the skin.

REFERENCES

- Alkharigy, F. A., El Naas, A. S., Maghribi, A. A. 2018. Survey Of Parasite in Domestic Pigeons (*Columba livia*) in Tripoli, Libya. *Open Veterinary Journal*. Vol.8(4) : 360 – 366
- Bernardeschi, C., Foulet, F., Ortonne, N., Sitbon, K., Quereus G., Lortholary O., Chosidow, O., Bretagne, S. 2015. Cutaneous Invasive Aspergillosis: Retrospective Multicenter Study of The French Invasive-Aspergillosis Registry and Literature Review. *Journal of Medicine*. Vol 94(26): e1018.
- Bogadanos, D. P., Gao, B., Gershwin, M. E. 2013. Liver Immunology. *Journal of Compare Physiology* 3 (2): 567 – 598
- Butcher, G. D, and Miles, R. 2018. *Avian Necropsy Techniques*.
- Djojodibroto, D. 2007. *Respirologi (Respiratory Medicine)*. Penerbit Buku Kedokteran ECG: Jakarta.
- Mohan, H. 2010. *Textbook Of Pathology Sixth Edition*. Jaypee Brothers Medical Publisher: New Delhi

- Latimer, S. K., Pauline M. Rakich, P. M., Branson, W. R., Harrison, G. J., Harrison, L R. 1994. Avian Medicine: Principles and Application. Wingers Publishing: USA.
- Majo, N and Dolz, R. 2011. Atlas of Avian Necropsy. Servet Publishing: USA
- Nakamura, K., Ohta, Y., Abe, Y., Imai, K., Yamada, M. 2010. Pathogenesis of Conjunctivits caused by Newcastle disease viruses in specific-pathogen-free chickens, Avian pathology journal. 33(3):371 – 376.
- Studdert, V. P., Gay, C. C. and Blood, D.C. 2012. Saunders Comperhensive Veterinary Dictionary, 4th. Sauders : Philadelphia.

