

# Sulfasalazine as an Alternative Therapy for Generalized Pustular Psoriasis: Case Series and Review of Literature

Jhauharina Rizki Fadhilla<sup>1\*</sup>, Eylene Meisyah Fitri<sup>1</sup>, Windy Keumala Budianti<sup>1</sup>, Endi Novianto<sup>1</sup>

<sup>1</sup>Department of Dermatology and Venereology Faculty of Medicine Universitas Indonesia/  
Dr. CiptoMangunkusumo National Central General Hospital, Indonesia

Keywords: Acitretin, methotrexate, psoriasis, sulfasalazine

Abstract: Generalized pustular psoriasis (GPP), psoriasis of von Zumbusch, is infrequent and notoriously intractable skin disease, so as the treatments remain challenging. One of the treatments of choice for GPP is acitretin currently used by most countries. Unfortunately, our national health regulation prohibits acitretin and also other systemic retinoids. Thus, sulfasalazine has been given to our patients due to poor response of cyclosporine and methotrexate (MTX) in previous treatment. We aimed to evaluate the efficacy of sulfasalazine in GPP. Three patients affected by GPP and unresponsive to previous treatment, received sulfasalazine started at the dosages of 1 gram/day. The dose was increased related to the response. We observed one patient with good result after 4 months administration. The other two stopped the treatment due to lack of response and severe digestive side effect. There were varied results of sulfasalazine therapy in GPP. It is known to act against molecular mechanism by inducing neutrophil apoptosis which is abundant in GPP pathogenesis. Sulfasalazine has warranty of its availability so far, affordable, and shares efficacy as well.

## 1 INTRODUCTION

Pustular psoriasis is a type of psoriasis clinically described by small to large pustules on erythematous skin. It is subtyped into generalized, localized variants, and drug-induced pustular psoriasis. Generalized pustular psoriasis consists of acute GPP, also known as von Zumbusch type, pustular psoriasis of pregnancy, and infantile and juvenile pustular psoriasis. Localized pustular psoriasis comprises palmoplantar pustular psoriasis and acrodermatitis continua of Hallopeau. Pustular psoriasis related drug-induced cases have been linked with various medications. (Gudjonsson JE et al, 2012; Sheu JS et al, 2016)

Based on histopathological analysis, pustular psoriasis lesions express neutrophil-dominant infiltrate. Large accumulations of neutrophils seen in the stratum corneum and surrounded by parakeratosis, culminate in abundant spongiform pustules of Kogoj and microabscesses of Munro. These histologic hints of “active” psoriasis are discerned in pustular psoriasis. (Gudjonsson JE et al,

2012; Kerkhof PC et al, 2018; Mansouri B et al 2016)

Therapy of GPP remains challenging as its rarity and heterogeneous nature of the disease. The clinical practice guidelines for psoriasis are based on a systematic review measuring skin symptoms as progression mostly (Fujita H et al, 2018; Twelves S et al, 2019). Fujita et al announced Japanese guidelines for GPP at 2018. They stressed on consideration that GPP is systemic inflammatory response syndrome (SIRS). Consequently, primary care, systemic maintenance, therapy of cutaneous lesions, and complications should be highlighted. (Twelves S et al, 2019). Both topical and systemic agents are regulated as GPP treatments, the latter including cyclosporine, MTX, acitretin, TNF $\alpha$  inhibitor, other biologics, (Fujita H et al, 2018; Twelves S et al, 2019) and granulocyte/monocyte adsorption apheresis (GMA). Despite its controversy, systemic corticosteroid is recommended in acute phase and as second-line therapy. (Fujita H et al, 2018; Twelves S et al, 2019) According to clinical practice guidelines released by Indonesian Society of Dermatology And

Venereology (INSDV), oral acitretin is recommended as monotherapy for pustular psoriasis and erythroderma psoriasis. (Kelompok Studi Psoriasis Indonesia Perhimpunan Dokter Spesialis Kulit dan Kelamin Indonesia, 2014).

Sulfasalazine is extensively used in treatments of inflammatory bowel diseases and rheumatoid arthritis; however, it is rarely as a systemic agent for treatment of GPP. (Gudjonsson JE et al, 2012; Niknahad H et al, 2017; Bertolotto M et al 2009). It is used in therapy-resistant disease or if the previous systemic agents are not well tolerated. Therefore, we report the consideration of sulfasalazine therapy as an alternative treatment in three cases of recalcitrant GPP.

## 2 CASE

### 2.1 Case 1

A 56-year-old female presented with a history of GPP for 30 years visited our DermatoAllergo-Immunology clinic. She came from Wonogiri, Central Java, and worked as a farmer. She came with chief complaint extensive scaly erythema and multiple pustules that form "lake of pus" on her trunk and extremities accompanied with systemic symptoms of fever and malaise. She had been treated with MTX (7.5-10 mg/week), topical and systemic steroids in 6 months. Methotrexate was stopped because the drug had not been available for weeks. The medication switched to azathioprine for a month. Regrettably, patient encountered anemia (hemoglobin level is 10.2 gr/dL). Because of that reason, we gave sulfasalazine with starting dose from 1000 mg per day combined with topical corticosteroid. After two weeks administration, patient revealed a new erythema with sterile pustules on her cheeks, and buttocks. We increased the dose to 1500 mg per day. After one month, the patient showed no more erythema and sterile pustules. She had taken sulfasalazine for 4 months. During last two months, she occasionally experienced a small number of sterile pustules which vanished after application of topical steroid for several times. We also evaluated factors that could trigger flares, include infection, smoking, and drugs.

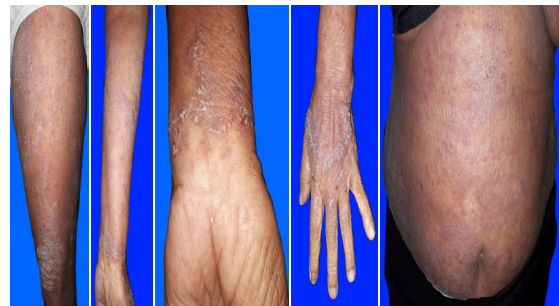


Figure 1. Erythematous plaques with sterile pustules and scale on left upper leg, lower left arm, left wrist, hand, and abdomen.

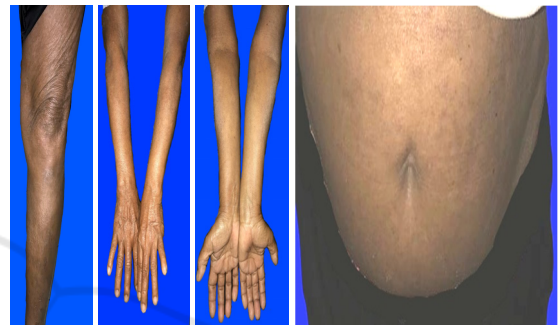


Figure 2. Evaluation after four months therapy of sulfasalazine revealed marked improvement.

### 2.2 Case 2

A 23-year-old female had psoriasis vulgaris since she was 11 years old. At the age of 13 years, she experienced GPP with no symptoms of psoriasis arthritis. She also had  $\beta$ -thalassemia as another comorbid. For years the disease was treated with acitretin, MTX, varying topical and systemic steroid with poor compliance because of economic burden. She also had been treated with cyclosporine for 8 months and had a temporary improvement. The GPP severity measured by body surface area, reduced up to 1.2%. But, grievously it relapsed again and cyclosporine did not help anymore. Then, MTX treatment replaced cyclosporine. It was started at the third month of oral anti-tuberculosis drug, with approval from an internal medicine specialist related to her pulmonary tuberculosis. She was still experiencing recurrent exacerbations of GPP for six months. We decided to replace MTX with sulfasalazine (1-2 gram/day) subsequently, combined with high doses until a maintenance dosage of oral methylprednisolone (4-20 mg/day). The severity was moderately improved while in addition with high dose systemic steroid. A year after, we terminated sulfasalazine and substituted by cyclosporine again.

### 2.3 Case 3

A 27-year-old female came to DermatoAllergo-Immunology clinic presenting with multiple pustules and extensive erythematous skin. She is a private school teacher whose planning to get married and refused to take any contraception. She had GPP for ten years and had been treated with multiple systemic agents. According to her history, combination of acitretin and antibiotic was very effective opposed to MTX and cyclosporine. She did not want to delay pregnancy after married, so we discussed about sulfasalazine as a therapeutic choice with the patient and family. She was agreed to be given 1000 mg sulfasalazine per day, but after one month, she experienced severe complaints related to her digestive tract, such as nausea, vomiting, loss of appetite, headache, and fatigue. On her own, she stopped treatment and treated herself by taking methylprednisolone 1x4 mg per day irregularly. Three months later, patient entered our emergency room with erythematous skin accompanied by sterile pustules that affect almost the entire body. Lastly, patient and her family are considering treatment with a biologic agent. While waiting, cyclosporine, topical and systemic steroid have been administered.

## 3 DISCUSSION

Acute GPP is a hazardous severe form of psoriasis that is life threatening. The typical findings are sterile pustules on erythematous base, and followed by constitutional symptoms. Varied triggering factors have been notified, including pregnancy (also named impetigo herpetiformis), consumption and withdrawal of corticosteroid, upper respiratory tract infections, emotional stress, and medicines.

Systemic corticosteroid usage and withdrawal is a notable factor that causes exacerbation of GPP by inducing inhibition of the inflammatory system.<sup>5</sup> All of our cases have been taking systemic corticosteroid, however we tapered the dose down slowly and with the addition of other systemic agents. However, it does not rule out the possibility of using steroids that trigger flares.

To preclude the infection, we consulted our patients to ears, nose and throat specialist, dentist, and sexually transmitted infections division. Infection can also cause to an acute activation of neutrophils which may affect as a trigger for the acute GPP. (Gudjonson et al, 2012; James WD, 2016; Fujita H et al, 2018)

Sulfasalazine acts as an anti-inflammatory

agent. (Bertolotto et al, 2009; Wright HL et al, 2010). Sulfasalazine has long been used in treatment of ulcerative colitis and Crohn's disease, also rheumatoid arthritis. (Akahoshi et al, 1997; Wright HL et al, 2010). The drug is composed of both sulfapyridine and 5-aminosalicylic acid (5-ASA). Sulfasalazine has various kinds of effects on leukocyte functions, namely inhibition on degranulation, chemotaxis, superoxide generation of neutrophils, proliferation and production interleukin-2, and also cytokine produced by monocytes. (Niknahad et al, 2017; Bertolotto et al, 2009). These mechanisms suggest that sulfasalazine plays a role in neutrophil-mediated diseases.

A case of acrodermatitis continua of Hallopeau (ACH), as one of the subtypes of pustular psoriasis, was reported successfully treated with sulfasalazine in the Department of Dermatology, the Hospital of Jiangsu University, Zhenjiang, China. The improvement reached after 2 weeks and total remission of skin lesions occurred after one-month therapy. (Li M et al., 2018). The first case we reported also showed good efficacy of sulfasalazine administration without being accompanied by other systemic agents for 4 months. The patient only received topical steroids.

The side effect profile of sulfasalazine includes headache, nausea, and vomiting, which occur in more or less one-third of patients. Hemolytic anemia can occur associated with glucose-6-phosphate dehydrogenase (G6PD) deficiency. Thus, it is important to work up baseline data of complete blood cell count (CBC), comprehensive metabolic panel (CMP), and G6PD. Repeat CBC and CMP weekly for 1 month, then every 2 weeks for 1 month, then monthly for 3 months, and then every 3 months. In this case report, we found one of three patients, the third case experienced gastrointestinal side effects such as nausea, vomiting, loss of appetite with headache and fatigue. Adherence to medication appears to also play a role in its success. The third case had a history of steroid use that does not comply with the recommendation of administration increases the risk of recurrent GPP. The other treatment that can be done is the biologic agent.

## 4 CONCLUSION

The three cases demonstrate both clinical benefit and failure that were received administration of sulfasalazine for GPP. The mechanism of sulfasalazine as an anti-inflammatory in skin diseases

is intricate; however, its efficacy in treating these clinically distinct cases of GPP suggests a different underlying pathophysiological mechanism. Based on this case series and a previous case report, sulfasalazine can be conceived as optional treatment choice for patients with GPP.

Wright HL, Moots RJ, Bucknall RC, Edwards SW. Neutrophil function in inflammation and inflammatory diseases. *Rheumatology*. 2010 Sep 1;49(9):1618–31.

Li M, Zhang Y, Xu H, Chen Z-Q, Li Y-M. A case of acrodermatitis continua of Hallopeau (ACH) successfully treated with sulfasalazine. *Dermatologic Therapy*. 2018 May;31(3):e12595.

## REFERENCES

- Gudjonsson JE, Elder JT. Psoriasis. In: Goldsmith LA, Katz SI, Gilchrist BA, Paller AS, Leffell DJ, Wolff K, editors. *Fitzpatrick's Dermatology in General Medicine*. 8th edition. New York: McGraw-Hill; 2012. p. 197-231
- Kerkhof PC, Nestle FO. Psoriasis. In: Bologna JL, Schaffer JV, Cerroni L, editors. *Dermatology* 4th edition. New York: Elsevier; 2018. p. 138-60
- James WD, Berger TG, Elston DM, Neuhaus IM. *Andrew's diseases of the skin*. 11th edition. Philadelphia: Elsevier; 2016. p. 185-98.
- Sheu JS, Divito SJ, Enamandram M, Merola JF. Dapsone Therapy for Pustular Psoriasis: Case Series and Review of the Literature. *Dermatology*. 2016;232(1):97–101.
- Mansouri B, Benjegerdes K, Hyde K, Kivelevitch D. Pustular psoriasis: pathophysiology and current treatment perspectives. *Psoriasis: Targets and Therapy*. 2016 Sep; Volume 6:131–44.
- Fujita H, Terui T, Hayama K, Akiyama M, Ikeda S, Mabuchi T, et al. Japanese guidelines for the management and treatment of generalized pustular psoriasis: The new pathogenesis and treatment of GPP. *The Journal of Dermatology*. 2018 Nov;45(11):1235–70.
- Twelves S, Mostafa A, Dand N, Burri E, Farkas K, Wilson R, et al. Clinical and genetic differences between pustular psoriasis subtypes. *Journal of Allergy and Clinical Immunology*. 2019 Mar;143(3):1021–6.
- Kelompok Studi Psoriasis Indonesia Perhimpunan Dokter Spesialis Kulit dan Kelamin Indonesia. Pedoman tatalaksana psoriasis dan *informed consent*; 2014. p. 16.
- Niknahad H, Heidari R, Mohammadzadeh R, Ommati MM, Khodaei F, Azarpira N, et al. Sulfasalazine induces mitochondrial dysfunction and renal injury. *Renal Failure*. 2017 Jan;39(1):745–53.
- Bertolotto M, Dallegrì F, Dapino P, Quercioli A, Pende A, Ottonello L, et al. Sulphasalazine accelerates apoptosis in neutrophils exposed to immune complex: Role of caspase pathway. *Clinical and Experimental Pharmacology and Physiology*. 2009 Nov;36(11):1132–5.
- Akahoshi T, Namai R, Sekiyama N, Tanaka S, Hosaka S, Kondo H. Rapid induction of neutrophil apoptosis by sulfasalazine: implications of reactive oxygen species in the apoptotic process. *Journal of Leukocyte Biology*. 1997 Dec;62(6):817–26.