

Giant Verruca Vulgaris on Scalp: A Case Report

Prilly Pricilya Theodorus^{1*}, Novriyani Masuku², Hanny Tanasal²

¹RSUD Dr. M. Haulussy – Ambon, Indonesia

²Departemen Dermatovenereologi RSUD Dr. M. Haulussy – Ambon, Indonesia

*Corresponding author

Keywords: Verruca vulgaris, histopathology, electrocauterization.

Abstract: Verruca Vulgaris (VV) or also called Common warts is a skin conditions that forms verrucose papules as a result of skin and mucosa proliferations that caused by Human Papilloma Virus (HPV). Authors reported a case of Giant Verruca Vulgaris on scalp in 18 years old male teenager, the lesion located in the left parietal that continuously increasing in size within two weeks. Lesion has a cauliflower-like appearance with nummular shape as big as 4x4x0,5cm and grayish-brown colored with verrucous surface on it. Histopathology findings' showed that the tissue perform a papillomatosis growth, epidermal hyperplasia, acanthosis, hyperkeratosis and parakeratosis, hypergranulosis with rough clod of keratohyaline, it also showed the upper epidermis has small core of coil cell, and hyperchromatic that surrounded by empty cytoplasm. The diagnose of VV were based on the clinical and histopathology findings. The selected treatment was electrocauterization (scar tissue presence after healing process).

1 INTRODUCTION

Warts are benign neoplasms caused by infection of epidermal cells with papillomaviruses (Miller et al, 2013). The thickening of the dermal cells with scaling and an upward extension of the dermal papillae containing prominent capillaries give them their warty of verrucous appearance (Miller et al, 2013; Androphy et al, 2012; Akram et al, 2015). Verruca Vulgaris or usually called Common warts is skin condition that usually comes with verrucous papules as a consequence of skin and mucosal proliferation that caused by Human Papilloma virus (HPV) (Cipto, 2015; Patrick et al, 2018). The main cause for VV is HPV type 2, followed by type 1 or 4 (Cipto, 2015). Incubations period vary from weeks to years, and 60% of the cases has spontaneous remission within 2 years without leaving scar tissue, if so, it is probably because of the treatment's method (Stockfleth, 2009). VV can be found in all ages, especially in children, adolescents, and young adults (Patrick et al, 2018; Beber et al, 2018).

HPV's transmission can occur from direct contact (skin-to-skin) by microabrasion in the superficial skin or through infected objects (e.g nail clipper) and environmental surroundings (swimming pool, because penetration is better when the skin is

in wet condition or broken) (Akram et al, 2015; Stockfleth, 2009; Beber et al, 2018). HPV infection mechanism can also occur through autoinoculation, wherein virus enter the epidermis through epithelium defect. Common predisposition factors are trauma, finger sucking, skin rubbing, and the presence of skin maceration (Haroen et al, 2008).

Physical examination usually presented with solid verrucous papule, keratotic, with the size ranging from a pin head to bigger than a centimeter, but the average size is usually around 5mm, and the lesion could go bigger as it goes confluent (Cipto, 2015; James et al, 2016). Variety of other shape such as cauliflower has tendency to appear on the neck and head, especially on scalp (warts usually bigger in size and exophytic) and beard area (in men appear because of shaving, as in women, they appear on legs) (Stockfleth, 2009; Beber et al, 2018). Predilection sites are fingers and hands (in areas that usually exposed to trauma that produce abrasion, e.g; elbow, knee, face, and fingers) and could be spread elsewhere (Stockfleth, 2009; Beber et al, 2018; Sterling, 2016). In immunocompromised patient lesions tend to be more extensive and hard to treat (Patrick et al, 2018; Bart, 2013).

Histopathology examination is performed to support the diagnosis and to eliminate hesitation in

diagnosing a case (Miller et al, 2013; Androphy et al, 2012; Cipto, 2015; Stockfleth, 2009). There are different types of treatment modalities to treat VV, but recurrences are common with all treatment modalities (Androphy et al, 2012). Children with common warts may not require treatment as spontaneous regression is frequent (Androphy et al, 2012). The management of warts depends on the degree of physical and emotional discomfort, the extent and duration of lesions, the patient's immunologic status, the patient's desire for therapy, and the risk of contagion to other persons (Androphy et al, 2012).

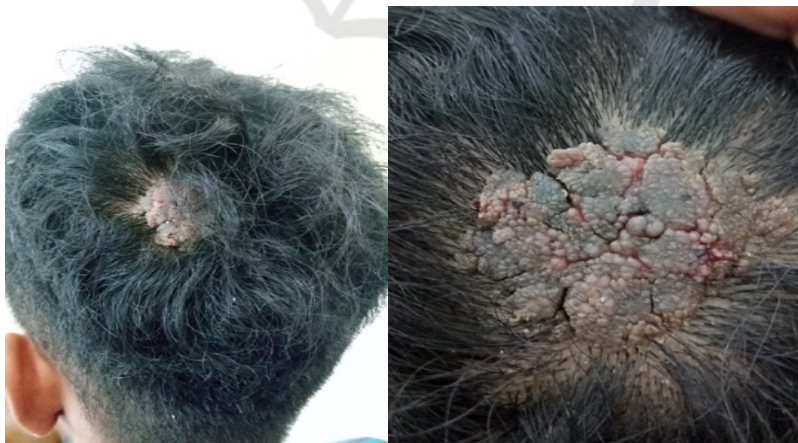In this case report, authors reported a case of Giant Scalp Verruca Vulgaris in 18 years old male teenager. The lesion grew in nummular shape at the left side of parietal region that continuously increasing in size within 2 weeks. The aim of this case report to show that manifestation of VV can occur in any part of the body (apart from the predilection site) and may develop in variative size.

2 CASE REPORT

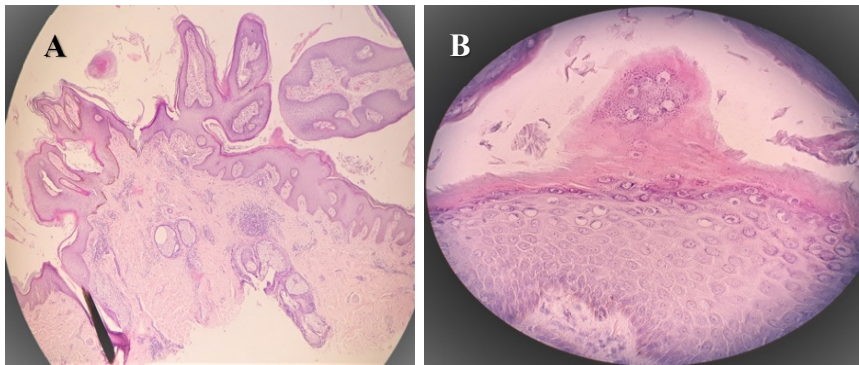
A 18 years old male teenager came to Dermatovenereology polyclinic at Dr.M. Haulussy General Hospital in December 6th 2018. He stated that he had a lump at the left side of his head that continuously grow bigger within 2 weeks. The lump cause no itching sensation, pain, and no prior trauma on the site of the lesion. During history taking,

patient stated that he had no contact with anyone surround him that has the same complain as he does. The lesion has never been treated before. Physical examination showed a grayish-brown cauliflower-like wart on the left side of the parietal with nummular size as big as 4x4x0,5cm and verrucous surface and a slight of blood on right side of the lesion. Laboratory test showed normal result and non-reactive to anti-viruses (HIV, HbsAg, anti-HCV).

Histopathology finding showed that the tissue perform a papillomatosis growth, epidermal hyperplasia, acanthosis, hyperkeratosis and parakeratosis, hypergranulosis with rough clod of keratohyaline, it also showed the upper epidermis has small core of coil cell, and hyperchromatic that surrounded by empty cytoplasm. Papilla dermis showed dilated capillaries that contains erythrocyte. The dermis layer contains sebaceous glands, hair follicle, eccrine gland, and perivascular lymphocyte infiltration. The treatment comprise electrocauterization with local anesthesia (scar tissue presence after healing process), analgetic (mefenamic acid 500mg t.i.d / p.o), wound compress with gauze using normal saline 0,9% (1x10 minutes before topical application), oral antibiotic (cefadroxile 500mg b.i.d / p.o for 5 days), topical antibiotic (fusidic acid 2 times a day/ TP), and multivitamin (vitamin B complex and vitamin C q.d / p.o for 5 days).

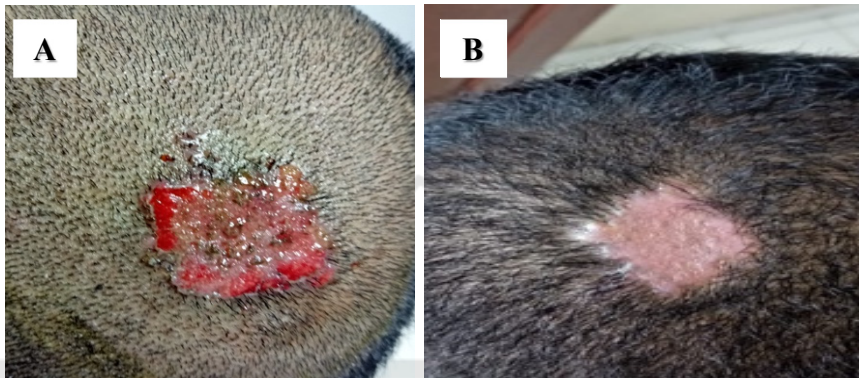


Picture 1. First clinical picture.
(reference: private documentation of Prilly in 2018)



Picture 2. Biopsy result (a) zoomed 40x (b) zoomed 400x.

(reference: Doc. of Pathology Anatomy Dept of Dr. M. Haulussy General Hospital in 2018)



Picture 3. (a) Post cauterization (b) Post healing process (scar)

(reference: private documentation of Prilly in 2019)

3 DISCUSSION

The diagnosis of VV in this case were based on history taking, physical examination, and histopathological finding. In history taking, authors found a 18 years old male teenager with a lump on the back of his head that increasing in size within 2 weeks. According to literature, VV is one of the manifestation that occur due to the presence of HPV infection.¹ VV can also be seen in any part of the body, happens in both male and female, and manifests in variety of age range, but mostly occur in children (during school age) and adolescents.⁶ HPV can be transmitted through direct contact and autoinoculation.^{2,4,6} The incubation period vary from couple of weeks to years.^{6,12}

In physical examination, a wart was found in the left parietal region with nummular shape as big as 4x4x0,5cm, with verrucous surface in it that covered in greyish-brown color and slight of blood at the right edge of the lesion. In case such as VV, lesion could be distinguished from normal skin because it interrupts the normal skin lines. This reflects the

convoluted epidermal surface (papillomatosis), hyperkeratosis, and often punctate bleeding into the stratum corneum.(Cipto,2015) Generally, wart's size vary from 1-10mm up to larger than a centimeter.(James et al,2016;Jr JGM et al 2013)

Lesion of VV tends to be exophytic, multiple, and irregular with rough nodules that arise in body part that often gets trauma or rubbed and has abrasion. Predilections site are those who often exposed to trauma, such as hands, fingers, elbow, knee and could spread elsewhere in the body. Warts can also appear in other unusual predilection site like the beard area, vermillion, and scalp could also (as for scalp, lesion tends to be bigger and exophytic).(Cipto,2015)

Initial diagnosis of this case was Giant Scalp Verruca Vulgaris with Seborrheic Keratosis (SK) and Epidermodysplasia Verruciformis (EV) as the differential diagnosis. Similar case report for Giant VV has been reported before in 2008 by Haroen et all, with different site of lesion. The lesion was located in dorsal pedis and has been going on for so

many years that it had developed keratinization. (Haroen et al, 2008).

In order to confirm the diagnosis, authors run for skin biopsy for histopathological testing and the result matched to Verruca Vulgaris. The result showed acanthosis (epidermal thickening), hyperkeratosis, papillomatosis, parakeratosis, and dilated vessels in the upper dermis (this cause blood to enter the stratum corneum and can be clinically visible, therefore the stratum corneum contains parakeratotic nucleus and blood). (Akram et al, 2015; Androphy et al, 2012; Beber et al, 2018). ;Cipto,2015;Patrick et al,2018).

The differential diagnosis with SK was removed because lesion in SK perform as papule with smooth or verrucous surface, covered in light brown to dark brown or similar to the skin tone (especially in dorsum manus), and happens in the elderly.(Sterling,2016) As for EV, the disease usually inherited genetically in a way that it's either autosomal dominant or recessive inheritance, and can't be found in general population like Verruca Vulgaris. (Beber et al, 2018)

Therapies consist personal care hygiene and avoidance of direct contact with infected person.⁴ Medical treatment has some option to perform, including topical medication (e.g; Cantharidin, 5-fluorouracyl, Imiquimod, Salicylic acid 25-50%, Tricloroacetate 25%, and phenol solution), destructive agents method (keratolytic), destructive surgery method (e.g; cryosurgery, electrocauterization, and CO₂ laser), and intralesional treatment (interferone and Bleomycin). (Androphy et al,2012; Cipto,2015;Jr JGM et al,2013;Patrick et al,2018)

The existence of multiple treatment modalities reflects the fact that none is uniformly effective or directly antiviral. (Androphy et al, 2012) Literature stated that most treatments for verrucae involve physical destruction of the infected cells and immunotherapy, but recurrences are common with all treatment modalities. (Androphy et al,2012; Bansal,2015;Cipto,2015). In this case, electrocauterization was considered to be more effective to eliminate the wart and to avoid patient's potentially non-compliance to the long course of topical treatment. The drawback side of electrocauterization is that it may cause scar tissue, pain, and can isolate the virus that it will cause recurrence. Authors did not perform HPV DNA identification because the limitation of modality in authors domicile. The last day of follow up showed the post treatment lesion has been healed with scar tissue remaining.

4 CONCLUSION

The diagnosis of Giant Scalp Verruca Vulgaris were made based on clinical and histopathological findings. Selected therapy was electrocauterization which was used to destruct the lesion, authors considered it to be more effective than topical application that it might decrease patient's compliance. Patient also were given oral antibiotic and topical antibiotic (applied on the lesion post electrocauterization) and also multivitamin. The last day of follow up showed the lesion has been healed with scar tissue remaining.

REFERENCES

- Akram S, Zaman H. 2015. *Warts and verrucas : assessment and treatment*. Pharm J. 7867(294): [6p.]. [Accessed on March 21st 2019]. Available from : <https://www.pharmaceutical-journal.com/learning/learning-article/warts-and-verrucas-assessment-and-treatment/20068680.article?firstPass=false>.
- Androphy EJ, Kirnbauer R. 2012. *Human papilloma virus infections*. Dalam: Goldsmith LA, Katz SI, Gilchrist BA, Paller AS, Leffel DJ, Wolff K. Fitzpatrick's *dermatology in general medicine*. 8th Ed. Vol.II. New York: McGraw-Hill; p.2421-33.
- Bansal R. 2015. *Essentials in dermatology, venereology & leprosy*. 1st Ed. Nepal: Jaypee Brothers Medical Publishers. p. 76-82.
- Bart B. 2013. *Viral infections of the skin*. In: Soutor C, Hordinsky MK. *Clinical dermatology*. 1st Ed. New York: McGraw-Hill Education. p. 88-96.
- Beber AAC, Benvegnú, Dallazem LND, Lages LN. 2018. *Viral Infections*. In: Bonamigo RR, Dornelles SIT. *Dermatology in public health environments*. 1st Ed. Switzerland : Springer Nature; p. 174-227.
- Citpo H. 2015. *Veruka vulgaris dan veruka plana*. In: Menaldi SLSW. Ilmu penyakit kulit dan kelamin. 7th Ed. Jakarta: Badan Penerbit FKUI; p.131-2.
- Haroen MS, Purba HM, Kartadjukardi E, Sularsito A. 2008. *Giant verruca vulgaris: a case report*. Med J Indones. 2(18): 135-8. [Accessed on March 21st 2019]. Diunduh dari: <http://mji.ui.ac.id/journal/index.php/mji/article/view/347>
- James W, Berger T, Elston D. 2016. *Andrew's disease of the skin*. 12th Ed. Philadelphia: Elsevier; p.399-403.
- Jr JGM, Miller JJ. 2013. *Lookingbill & Marks' principles of dermatology*. 5th Ed. Philadelphia: Elsevier; p. 55-8.
- Patrick Bacaj and David Burch. 2018. *Human papillomavirus infection of the skin*. Arch Pathol Lab Med. 6(142): 700-705. [Accessed on March 25th 2019]. Diunduh dari : <https://www.archivesofpathology.org/doi/full/10.5858/arpa.2017-0572-RA>.

- Sterling JC. 2016. *Human papilloma virus infections*. In: Griffiths C, Barker J, Bleiker T, Chalmers R, Creamer D. *Rook's textbook of dermatology*. 9th Ed. Vol.I. Oxford: Wiley. ch. 25.43-61.
- Stockfleth E. 2009. *Human papilloma virus infections*. In: Burgdorf WHC, Plewig G, Wolf HH, Landthaler M. *Braun-Falco's dermatology*. 3rd Ed. German: Springer; p.64-73.

