

# Pediatric Psoriasis in Patient with Obesity

Elin Herlina<sup>1\*</sup>, Eunice Gunawan<sup>1</sup>, Retno Indar Widayati<sup>1</sup>, Widyawati<sup>1</sup>, Indra Wijaya<sup>1</sup>

<sup>1</sup>Departement of Dermatovenereology, <sup>5</sup>Departement of Anatomic Pathology Faculty of Medicine Diponegoro University /  
Dr. Karyadi General Hospital Semarang

\*Corresponding author

**Keywords:** Childhood psoriasis, psoriasis vulgaris, pediatric psoriasis.

**Abstract:** Psoriasis is an immunologically mediated chronic inflammatory skin disease, characterized by well-defined salmon-pink plaques bearing large adherent silvery centrally attached scales. The prevalence in children aged 10-19 years is about 1.37%. Pediatric psoriasis has been associated with specific comorbidities, such as obesity, hypertension, hyperlipidemia, diabetes mellitus, and rheumatoid arthritis, making early diagnosis and management essential. A 12-year-old boy whose body weight was 120 kilograms presented with erythematous patches and plaques covered by thick silvery scales on his face, trunk, belly, elbows, lower limbs, and knees. Patient felt itchy on those lesions. The diagnosis was made based on clinical history, clinical examination, and histopathology examination. Histopathological examination showed tissue covered by keratinized stratified squamous epithelium, hyperkeratotic, parakeratotic, acanthosis, regular rete ridges, the dermis consisted of skin adnexa and fibro collagenous stroma connective tissue with perivascular lymphocytes. The patient was treated with Methotrexate 5mg per 12 hours given on the first and second day of every week, folic acid 1 mg per day is given on the third to seventh day every week, 0.25% desoximetasone cream and 10% urea cream twice daily. Information, education, communication, and psychological support were provided to the patient and his parents. A good response was observed after two months of treatment.

## 1 INTRODUCTION

Psoriasis is a chronic inflammatory hyperproliferative disease of the skin, scalp, nails, and joints. Psoriasis is an inherited papulosquamous skin disorder with a variety of clinical presentations, most of which eventuate into well-defined erythematous lesions with typical silvery scales (Bronkers et al, 2015). The prevalence of psoriasis in childhood is about 0.55 % in children aged 0–9 years and 1.37 % in children aged 10–19 years (Bronkers et al, 2015).

Psoriasis in children can have a significant impact on the quality of life by interfering with self-esteem, family and social relationship and school. Children suffering from psoriasis also have a higher prevalence of comorbidities, including obesity, diabetes mellitus, hypertension, rheumatoid arthritis, Crohn's disease, and psychiatric disorder (Bronkers et al, 2015).

Psoriasis flares can be provoked by non-specific triggers. A higher frequency of stress (associated

with the start of the school year, the birth of brother/sister, etc.), mild trauma (Koebner phenomenon), and infection (streptococcal, viral) were reported. Systemic drugs (beta-blockers, lithium, antimalarial, etc.) or HIV infection, are less frequently implicated in children than in an adult (Mahe, 2016).

Plaque psoriasis is the most common form of pediatric psoriasis. The presentation in children resembles psoriasis in adults. However, initial lesions are less prominent, with mild scaling and induration. In later stages, the clinical presentation is dominated by scaly plaques accompanied by itching. Psoriasis frequently affects elbows, knees, scalp, umbilicus, and face (Mahe, 2016; Madiraca et al, 2016).

Treatment of psoriasis in the pediatric patient is challenging because lack of clinical trial and guidelines. There are currently no international standardized guidelines for medical treatment of pediatric psoriasis. Treatment options include topical agents, systemic agents, biologic agents, and phototherapy. Treatment success depended mainly

on parental involvement and education. Psychosocial support is another critical component of therapy for children with psoriasis (Bronkers et al, 2015; Madiraca et al, 2016).

## 2 CASE

A 12-year-old boy, Javanese, Indonesian, came to Dermatovenereology Department Kariadi General Hospital Semarang on 23 August 2018 with itchy erythematous plaques and thick silvery scaling all over his body for several years. The plaque first appeared on the face, trunk, belly, elbows, and knees.

The mother said since he was 5-year-old, erythematous spots and scales had started to appear on her son's body and get worse, the patient had never been treated.

The patient is the second child, the father works as a trader in the market, and the mother is unemployed. Medical expenses are covered by the Social Insurance Administration Organization/*Badan Penyelenggara Jaminan Sosial* (BPJS). The socioeconomic impression is sufficient.

The patient whose body weight was 120 kilograms with BMI 43 belonged to the obese category, and the health conditions, in general, were perfect. Physical examination on the face, trunk, belly, elbows, lower limbs and knees found several lesions presented as well-defined erythematous plaques that were partially covered by thick silvery scales. Auspitz test was positive (+). Laboratory examination found hemoglobin level of 15.7 g/dL, SGOT 22 U/L, SGPT 60 U/L, Urea 22 mg/dL, Creatinine 0.79 mg/dL, blood sugar 81 mg/dL, which were all within the normal limit.

Histopathology examination showed tissue covered by keratinized stratified squamous epithelium, hyperkeratotic, parakeratotic, acanthosis, regular rete ridges, the dermis consisted of skin adnexa and fibro collagenous stroma connective tissue with perivascular lymphocytes. No signs of malignancy. The 10% Potassium hydroxide test did not find any hypha or spores.

The diagnosis of this patient was psoriasis Vulgaris with a PASI score of 19.9. The patient was treated with Methotrexate 5mg per 12 hours given on the first and second day of every week, folic acid 1 mg per day is given on the third to seventh day every week, 0.25% desoximetasone cream applied to the lesion twice a day and 10% urea cream was applied twice a day as a moisturizer. Therapy was

done for two months, a significant improvement was found.

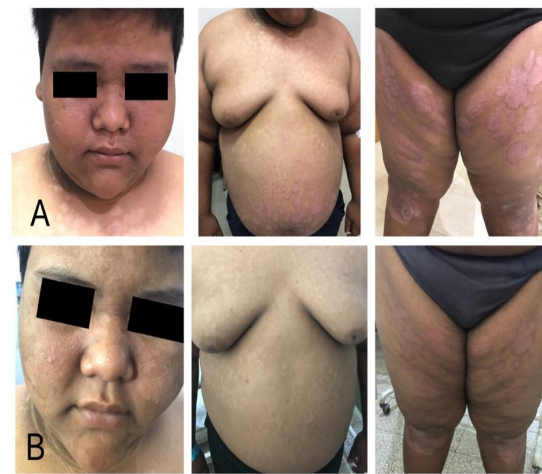


Figure 1. (A) First observation there were erythematous plaques and silvery scales (B) Second observation after two months therapy

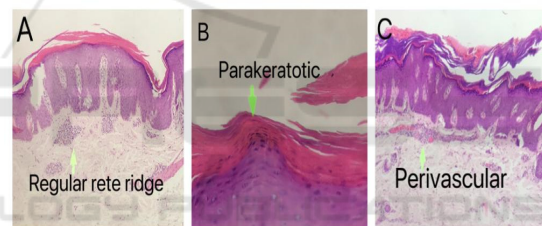


Figure 2. Histopathologic Findings

## 3 DISCUSSION

A 12-year-old boy with well-defined erythematous plaques, partially covered by thick silvery scales on the face, trunk, belly, elbows, lower limbs and knees. According to the references, the disorder may present in 1.37% children aged 10–19 years with solitary lesions or countless plaques in a generalized distribution. (Bronkers et al, 2015; De Waard-van der Spek et al, 2011).

There was no history of psoriasis in his family. A child with one affected parent has a 14% chance of developing psoriasis disease, and this rises to 41% if both parents are affected. (Fortina et al, 2017) The prevalence of psoriasis patients with an affected family member is observed to be higher in early-onset psoriasis (before age 16) than in adult-onset psoriasis (after age 16). (Bronkers et al, 2015).

The patient whose body weight was 120 kilograms with BMI 43 belonged to the obese category, but this patient had an excellent metabolic condition. In the literature, obesity as a comorbidity of psoriasis has been the focus of much investigation, and the large international cross-sectional study has demonstrated the increased risk of being overweight or obese in pediatric psoriasis in 5- to 17-year-old children with psoriasis. (Bronkers et al, 2015).

Dermatological examination showed erythematous plaques, partially covered by thick silvery scales on face, trunk, belly, elbows, lower limbs, and knees. Positive auspitz sign. According to the references psoriasis in children is often similar to that seen in adult patients. The lesions are well-defined, erythematous, and papulosquamous, with silvery scales. The successive removal of psoriatic scales produces small bleeding points where the thin suprapapillary epitheliums are torn off (Auspitz Sign). (De Waard-van der Spek FB et al, 2011).

Although the diagnosis of psoriasis is primarily based on clinical features, a biopsy can help to confirm the diagnosis in children. Analysis of a skin biopsy specimen from the patient showed tissue covered by keratinized stratified squamous epithelium, hyperkeratotic, parakeratotic, acanthosis, regular rete ridges, the dermis consisted of skin adnexa and fibro collagenous stroma connective tissue with perivascular lymphocytes. Histological features of psoriasis include parakeratosis, loss of granular cell layer, elongation of the rete ridges, neutrophilic aggregates within the epidermis (microabscesses of Munro) especially common in early lesions, dilated blood vessel in the dermis, and perivascular lymphocytic infiltrates. These characteristics may vary depending on site of biopsy, psoriasis subtype, and whether children have been treated with topical and or systemic treatment. (De Waard-van der Spek FB et al, 2011; Rapini, 2005).

The differential diagnosis of tinea corporis could be excluded because the lesion in tinea corporis showed enlarging raised red rings with a central area of clearing, mycological examination (+). (Fortina et al, 2017) Patient's 10% potassium hydroxide test result did not find any hypha or spores.

The patient was treated with Methotrexate 5mg per 12 hours three times per week and folic acid 1mg per day given except on the day of methotrexate therapy. From the results of this patient's laboratory, there were no contraindications for methotrexate therapy. Methotrexate is considered

the systemic treatment of choice for children with moderate-to-severe plaque psoriasis. However, its use in childhood is also appropriate for PsA, extensive, recalcitrant, severe or disabling psoriasis, and erythrodermic or generalized pustular disease resistant to topical and phototherapy. In children, methotrexate advantages include the efficacy and weekly oral dose (0.2–0.7 mg/kg/week). Dose escalations of 1.25–5 mg/week until the achievement of clinical benefits, followed by a slow taper to a maintenance dosage, are advised. Based on a study, acitretin, MTX and CsA may be considered as first-line therapy for childhood psoriasis with acceptable efficacy and few adverse effects, with acitretin seeming efficient on a plaque, pustular and palmoplantar psoriasis, methotrexate on plaque and guttate psoriasis, and CsA on erythrodermic and palmoplantar psoriasis. Folic acid is routinely administered to improve tolerability and decrease the appearance of nausea, macrocytic anemia, pancytopenia, and hypertransaminasemia. Some authors prescribe folic acid two days after every methotrexate dose, while others recommend daily except on the day of methotrexate therapy (Napolitano et al, 2016).

Topical 0.25% Desoxymethason cream was given twice a day. Topical corticosteroids have a vital role in treatment due to antiproliferative, anti-inflammatory, immunosuppressive, and vasoconstrictive properties. Desoxymethason is a potent corticosteroid that can be used on thick psoriatic plaques (Madiraca et al, 2016). Emollients are used as adjunctive agents to decrease the associated scaling and dryness but should not replace medications when inflammation is present. (Paller et al, 2011)

#### 4 CONCLUSION

A 12-year-old patient with psoriasis vulgaris and obesity. The diagnosis was based on the anamnesis and the clinical features, as well as on histopathological examinations of our patient's tissue specimens. The combination treatment of Methotrexate and topical corticosteroid successfully reduced the PASI Score to 9.9. The prognosis was *quo ad vitam ad bonam, ad sanam dubia ad bonam, ad cosmeticam ad bonam*.

## REFERENCES

- Bronckers IMGJ, Paller AS, Van Geel MJ, Van De Kerkhof PCM, Seyger MMB. 2015. *Psoriasis in Children and Adolescents: Diagnosis, Management and Comorbidities*. June; 17: p. 373-384.
- Callen J. P. 2008. *Immunosuppressive and Immunomodulatory Drugs*. In: Goldsmith L. A, Katz S.I, Gilchrist B.A, Paller A. S, Leffell D. J, Wolff K, editor. *Fitzpatrick's Dermatology in General Medicine*, 8<sup>th</sup> edition. New York: McGraw Hill. p. 2807-2814
- De Waard-van der Spek FB, Oranje AP. 2011. *Psoriasis*. In: Irvine A, Hoeger P and, Yan A, editor. *Harper's Textbook of Pediatric Dermatology*, 3<sup>rd</sup> edition. West Sussex: Blackwell Publishing Ltd. p. 80.1-80.7
- Dogra S, Bishnoi A. 2018. *Childhood psoriasis: what is new and what is news*. Volume 19. October-December ; p. 308-314
- Fortina A.B, Bardazzi F, Berti S, Carnevale C, Lernia VD et al. 2017. *Treatment of Severe Psoriasis in Children: Recommendations of an Italian Expert Group*. August
- MadiracaD, Situm M, Prkacin I, Bulic SO. 2016. *Treatment Options for Pediatric Psoriasis*. February; 24(3): p. 175-180
- Mahe E. 2016. *Childhood Psoriasis*. November. 26(6): p. 537-48
- Napolitano, Megna M, Balato A. 2016. *Systemic Treatment of Pediatric Psoriasis: A Review*. April; 6: p. 125-142
- Paller A.S, Mancini A.J. 2011. *Hurwitz Clinical Pediatric Dermatology*. 4<sup>th</sup> edition. New York: Elsevier Saunders. p. 71-91.
- Rapini R.P. 2005. *Practical Dermatopathology*. Elsevier Mosby. p.51-52
- Weller R.B, Hunter H.J.A, Mann M.W. 2015. *Psoriasis*. In. *Clinical Dermatology*, 5<sup>th</sup> edition. West Sussex: John Wiley & Sons Ltd. p. 52-67