

# Vitiligo on Vogt-Koyanagi-Harada Disease

Meiza<sup>1\*</sup>, Irvin Aldikha<sup>1</sup>, Renni Yuniati<sup>1</sup>, Radityastuti<sup>1</sup>, Meira Dewi Kusuma Astuti<sup>2</sup>

<sup>1</sup>Department of Dermatovenereology, Faculty of Medicine Diponegoro University / Dr. Kariadi General Hospital

<sup>2</sup>Department of Pathological Anatomy Faculty of Medicine Diponegoro University / Dr. Kariadi General Hospital

\*Telephone: 081360022801; email: meiza.dvjan18@gmail.

**Keywords:** Vogt-Koyanagi-Harada Disease, vitiligo, poliosis

**Abstract:** Vogt-Koyanagi-Harada (VKH) disease is a rare granulomatous inflammatory disease that affects the pigmented structure. The etiopathogenic of this syndrome remains unclear; it is proposed as an autoimmune disorder. Diagnosis of VKH is made based on at least 3 of the following four criteria of The American Uveitis Society (Bilateral iridocyclitis, posterior uveitis, neurological sign, cutaneous findings of vitiligo, poliosis or alopecia) and an absence of prior trauma or surgery. Treatment for repigmentation of vitiligo is non-surgical and/or surgical, which yields good results. This case report is aimed to give more understanding of the diagnosis and management of vitiligo on VKH. A 47-year-old male with the complaint of white spots presented previously on the face for three weeks. The patient was referred from the ophthalmology department with bilateral iridocyclitis and panuveitis. There was no hearing loss. From the physical examination, hypopigmented macules and poliosis were found on the eyebrows. Histopathological examination supported the diagnosis of vitiligo. The patient was treated with methylprednisolone tablet 16 mg 2-0-1, and fluticasone propionate cream 0.05% every 12 hours on the affected skin. The prognosis of this patient was *quo ad vitam ad bonam quo ad sanam ad malam and quo ad cosmeticam dubia ad bonam*. In this case, we found 3 of the four criteria of diagnosis is Bilateral iridocyclitis, posterior uveitis, cutaneous findings of vitiligo, and poliosis. The patient was given high potency topical corticosteroids twice daily and oral corticosteroid. It showed significant clinical improvement after four months.

## 1 INTRODUCTION

Vogt Koyanagi Harada Disease is a rare granulomatous inflammation that can affect pigmentation structure, where the main target is a cell which contains melanin on eyes, inner ear, brain membrane, skin, and hair (Lavezzo et al, 2016; Sakata et al, 2014; Anstery, 2010). In the beginning, VKH disease can be conceived as an uveomeningoencephalitis syndrome (Lavezzo et al, 2016).

In 1906, Swiss's ophthalmologist residency student Alfred Vogt described the disease as bilateral subacute iridocyclitis with early bleaching on eyelashes. In 1926, Einosuke Harada reported 5 cases with posterior bilateral uveitis and retina exfoliation after the inflammation is decreased. Close with that time in 1929, Koyanagi published an article that explained the pathogenesis of the disease, includes prodromal phase, acute uveitis phase with the involvement of posterior segment, the recovery phase followed by hearing and skin manifestation. In

1932, Babel advised this disease is on the same form with later named Vogt Koyanagi Harada (Lavezzo et al, 2016; Sakata et al, 2014; Anstery, 2010).

Vogt Koyanagi Harada disease often affects the individual with darkly pigmented people such as in Asia, Hispanic, Origin American and Hindian and Brazilian (Lavezzo et al, 2016; Burkholder, 2015; Bilgic et al, 2014; Su et al, 2018). Most of the research informed that woman affected more than a man with ratio 2:1 (Lavezzo et al, 2016; Burkholder, 2015; Bilgic et al, 2014; Ng et al, 2014). Most of the patients are on the second to fifth decade of the life with a peak of the event on third and fourth (Lavezzo et al, 2016; Burkholder, 2015; Bilgic et al, 2014; Bayer, 2016). Elderly and children can be affected by the disease, and although it is rare, one author reported that the youngest patient is three years old girl (Lavezzo et al, 2016; Burkholder, 2015; Bayer, 2016). The prevalence and incidence of VKH is a rare disease. In the USA the incidence of VKH is about 1,5 – 6 cases per 1 million patients while in Japan is about 800 new cases annually (Lavezzo et al, 2016).

Etiology and pathogenesis of Vogt Koyanagi Harada suspected to be a systemic autoimmune disease which clearly unknown (Lavezzo et al, 2016; Burkholder, 2015; Su et al, 2018). The Vogt Koyanagi Harada may be systemic autoimmune disease on melanosis that affects mainly on eyes, inner ear, and brain membrane and skin (Lavezzo et al, 2016; Su et al, 2018). An author has reported a case that one of the triggers of this disease is an infectious agent such as Epstein-Barr Virus & Cytomegalovirus. Trauma on the skin can be one of the etiology of the disease, even though the causative relationship between the virus and the disease have not been established yet (Lavezzo et al, 2016; Burkholder, 2015; Ng et al, 2014).

The diagnosis of VKH disease was based on the American Uveitis Society (AUS) criteria. The physical examination also some criteria that have been made to be diagnostic approachment (Lavezzo et al, 2016; Sakata et al, 2014). The diagnosis of Vogt Koyanagi Harada disease was based on criteria made by American Uveitis Society (AUS) criteria on 1978 and Sigiura's criteria on 1976 (Lavezzo et al, 2016). American Uveitis Society recommend, without history of trauma and eyes surgery procedure, at least there are 3 or 4 other criteria to diagnose VKH disease, which are iridocyclitis bilateral, posterior uveitis, neurology abnormality, and skin abnormality likes vitiligo, poliosis, or alopecia. The accurate diagnosis of VKH disease can prevent complication (Bilgic et al, 2014).

The active and adequate treatment on early phase can reduce the risk to recurrent. The early treatment and aggressive corticosteroid are the best treatment for this disease on acute uveitis phase, and also corticosteroid treatment on this acute phase can reduce the risk of lost sight permanently (Lavezzo et al, 2016; Sakata et al, 2014; Burkholder, 2015; Ng et al, 2014). The dosage of systemic corticosteroid is given by oral is prednisone 1-1.5 mg/KgBB/Day, or, methylprednisolone 1 gr/day for three days. Treatment with corticosteroid must reduce slowly and last at least for six months (Lavezzo et al, 2016; Ng et al, 2014). The treatment for skin depigmentation is the same with vitiligo treatment (Bayer, 2016).

## 2 CASE

A 47 years old man, came with complaint of having some white spots for three weeks ago. The white spots appear on the face, It has been starting from the chin and spreading through cheek, nose, and

forehead, the white spots are not itchy, and the patient did not apply topical regimen to the spots. His eyelashes had been starting to bleach when he came to the hospital. The patient was referred from the ophthalmology department. One year prior, the patient suffered from fever, pain on eyes, and blurry sight, headache without a history of trauma or eyes surgery. In the ophthalmology department, the patient is diagnosed with panuveitis and iridocyclitis bilateral. On that time, there were no hearing symptoms of ear buzzing and had no white spots on face. The wound on the Genitalia was denied, no similar history or symptoms in his family. General condition was compos mentis, well nourished with height 165cm and weight 63kg, blood pressure is 120/80mmHg, respiratory rate 18x/m, and heart rate is 80x/m, and axilla temperature is 37°C. Physical examination, dermatology status is found hypopigmented macules on face and poliosis on dermatologic examination.

On laboratory testing the hemoglobin was 15 gr%; leucocytes 5.500/mm<sup>3</sup>; eritrocytes 4,3 juta/mm<sup>3</sup>; trombocytes 231.000/mm<sup>3</sup>; ureum 15 mg/dl; creatinin 0,8 mg/dl; SGOT 14 U/I; SGPT 45 U/I. VDRL and TPHA are negative.

The histopathologic examination found flat sprained epithelial, creatine, *follicular plugging*, and melamine pigment is not equal, stroma subepithelial plain, contain sebaceous gland that suitable of vitiligo. Diagnosis of this patient was Vogt Koyanagi Harada disease. The treatment of vitiligo to this patient is active potential topical corticosteroid fluticasone 0,05 % applied every 12 hours on the face, and a systemic corticosteroid is metilprednisolon 16 mg tab 2-0-1.

Repigmentation was found in the first month of observation. Good clinical improvement was observed after four-month.

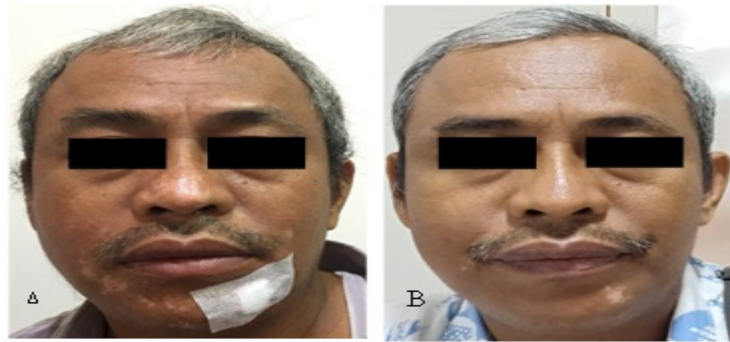

Figure 1. (A) Examination on the first month (B) Examination on the fourth month

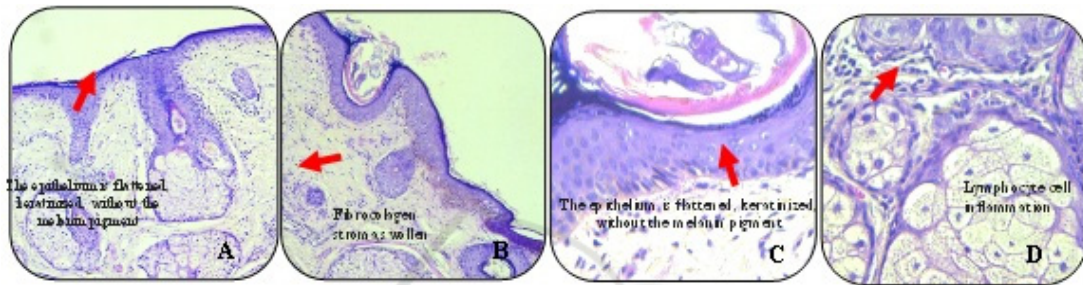


Figure 2. Microscopic histopathology

### 3 DISCUSSION

Vogt Koyanagi Harada (VKH) disease shows some manifestation, in clinical side VKH disease, has 4 phases, an early phase is a prodromal phase or called meningoencephalitis phase, which happens for 3-5 days with a flu-like syndrome, fever, headache, orbital pain, hearing problems, tinnitus and neurology symptoms. On this phase, the cerebrospinal fluid test will show limonitic pleocytosis that happens for some weeks.

In this case, patient had suffered from prodromal phase such as fever, pain in eyes, headache for 1 week, afterward patient had the second phase which was acute uveitis generally happens on the 3th days until 5th days from prodromal phase and occurs for some weeks until several months, with blurry vision, photophobia, pain on eyes, loss of vision in one or both of eyes. The patient was diagnosed with panuveitis, and iridocyclitis bilateral by the ophthalmologist with clinical symptoms is a blurry vision, but the patient has no dysacusis, tinnitus, or other hearing problem. The 3rd phase or convalescence phase occurs some weeks after acute uveitis phase. This phase started with depigmentation, progressive tissue; on this stage, there is skin involvement with vitiligo appearance,

poliosis, and alopecia. The clinical symptoms on the skin occur for some months or even some years. (Lavezzo et al, 2016; Sakata et al, 2014; Burkholder, 2015; Bilgic et al, 2014)

Vitiligo develops on 19-90% cases, vitiligo usually symmetrical and can occur in every area of the body likes on face and back area are the most common. The histopathologic finding showed there was no melanosis. Poliosis occurs most on eyebrows, eyelashes, and scalp. Alopecia can occur as areata alopecia or diffuse hair loss (Burkholder, 2015; Bilgic et al, 2014; Ng JY et al, 2014) On the third phase, and this patient had vitiligo that was spreading, followed by poliosis on eyebrows.

The diagnosis of Vogt Koyanagi Harada was based on clinical symptoms. Some criteria have been made to achieve the diagnostic, include America Uveitis Society on 1978, Sugiura on 1976. On 1999, an international workshop for some expert made diagnosis revision, the criteria published on 2001 which has three categories such as Complete Vogt Koyanagi Harada disease, Incomplete Vogt Koyanagi Harada, and suspect Vogt Koyanagi Harada. (Lavezzo et al, 2016; Sakata et al, 2014; Anstery et al, 2010)

From these three categories, there are absolute requirements: bilateral eyes problem, no history of trauma or eyes surgery. (Burkholder, 2015)

**Revised Diagnosis Criteria on the international workshop I in 2001<sup>2</sup>**

Complete disease (Criteria 1-5 must be found)

1. There is no history of ocular trauma or surgery before the initial onset of uveitis
2. There is no clinical evidence that shows other eye diseases
3. The involvement of both eyes
  - a. Rapid disease manifestations
    - Diffuse choroiditis
    - Alternatively, the characteristics of fluorescein angiography and echography findings are diffuse choroidal thickening
  - b. Slow disease manifestations
    - History of previous uveitis with the characteristics described above
4. Symptoms of nerves and symptoms of hearing
5. Integumentary symptoms (alopecia, vitiligo, or poliosis)

Incomplete disease (Criteria 1 to 3 plus one of 4 or 5 must be found)

Possible disease (Isolated eye disease, criteria 1 to 3 must be found)

This patient was suitable with the incomplete Vogt Koyanagi Harada disease are met. This patient has no history of penetrating ocular trauma and surgery at the onset of uveitis and no laboratory results that support other eye diseases.

Differential diagnosis with Alezzandrini's syndrome can be ruled out. Alezzandrini syndrome is characterized by ipsilateral facial vitiligo, with unilateral taporetinal regeneration of the eyes, white hair, poliosis, and hearing loss. Vitiligo facials and poliosis in the eyebrows and eyelashes usually occur after several years of abnormalities in the eye. (Anstery et al,2010;Bilgic et al,2014;Bleue,2016) In this patient found facial vitiligo accompanied by poliosis in the eyebrows and panuveitis with bilateral iridocyclitis. Treatment of vitiligo in Vogt Koyanagi Harada disease can be treated according to vitiligo.(Bayer,2016) The main goal of vitiligo therapy is repigmentation, while the secondary goals include stabilization of the disease to stop the loss of functional melanocytes, and ensure adequate psychosocial care and quality of life. (Bleue,2016)

Specific therapy for vitiligo repigmentation can be done surgically and non-surgical.<sup>10</sup>

Grafting can be done surgically such as punch grafts, blister grafts, split-thickness skin grafts, and hair follicle grafts. Surgical therapy is only recommended for patients with a stable history of the disease for the past 6-24 months and should only be used for small size lesions. The surgical procedure is generally followed by a 3-4 week phototherapy procedure. (Bleue,2016;Stanca et al,2012) Topical treatments can be given, including corticosteroids topical, calcineurin inhibitors, calcipotriol, topical vitamin D analogs. Physical therapy with UVB, PUVA, laser excimer. Systemic therapy with corticosteroid use. (Bayer, 2016;Bleue, 2016;Stanca et al,2012).

Corticosteroids are the first-line therapy for localized vitiligo and are highly recommended for faces or small size lesions, and for children, the benefit of corticosteroid is easy to use low cost compared to PUVA. PUVA has proven to be less effective and has more side effects compared to UVB. (Bleue,2016;Stanca et al,2012)

The prognosis of this patient was *quo ad vitam ad bonam, quo ad sanam dubia ad malam, quo ad cosmetikam dubia ad malam*. Inadequate treatment is the main factor associated with worse prognosis.<sup>2</sup> Improvements in visual impairment depend on the rapid and precise management, and ocular symptoms are usually right. Disorder of the skin may be permanent last longer. (Bilgic et al,2014;Stanca et al,2012)

## 4 CONCLUSION

A case of patient vitiligo in Vogt Koyanagi Harada disease was reported in a 47-year-old male patient, and Physical examination found hypopigmented macules on the face and poliosis on the eyebrows. Histopathologic examination was suitable with vitiligo. Vogt Koyanagi Harada disease Therapy with systemic and topical corticosteroid after four months gave good clinical result. The prognosis of the patient was *quo ad vitam ad bonam, quo ad sanam dubia ad malam, quo ad cosmetikam dubia ad malam*

## REFERENCES

- Anstery AV. 2010. *Disorders of skin colour*. In: Burns T, Breatnach S, Cox N, Griffith C, editors. Rook's



- Textbook Of Dermatology, 8<sup>th</sup> edition. Weat Sussex: Blackwell Publishing.. p.58.45-46
- Bayer ML. 2016. *Successful Treatment of Vitiligo Associated with Vogt–Koyanagi*. 1-2
- Bilgic O, Abuzer G, Kaya K. 2014. *Vogt-Koyanagi-Harada Disease in an Adolescent Boy*. Pediatric Dermatology. 99–101.
- Bleue R, Eberlein B. 2018. *Therapeutic management of vitiligo*. *Deutsche Dermatologische Gesellschaft (DDG)*. 1-5
- Burkholder MB. 2015. *Vogt–Koyanagi–Harada disease*. *Curr Opin Ophthalmol*. 26:506–11.
- Lavezzo MM, Sakata VM, Morita C, et.al. 2016. *Vogt-Koyanagi-Harada disease: review of a rare autoimmune disease targeting antigens of melanocytes*. *Orphanet J Rare Dis*.11(29):1-21.
- Ng JY, Luk OJ, Lai YY, et.al. 2014. *Influence of molecular genetics in Vogt-Koyanagi-Harada disease*. *Journal of Ophthalmic Inflammation and Infection*. 4(20):1-12
- Sakata VM, Silva FT, Hirata CE, et.al. 2014. *Diagnosis and classification of Vogt–Koyanagi–Harada disease*. *Autoimmunity Reviews*. 1-6.
- Stanca AB, Richard AS, David AN. 2012. *Vitiligo*. In: Wolff, K, et.al. Gold Smith L, Katz S, Gilchrest, Palle A, Editors. *Fitzpatrick’s Dermatology In General Medicine*.8<sup>th</sup> edition. New York: Mc. Graw Hill. p. 792-803
- Su E, Oza. SV, Latkany P. 2018. *A case of recalcitrant pediatric Vogt-Koyanagi-Harada disease successfully controlled with adalimumab*. *Journal of the Formosan Medical Association*. 1-6

