






The Lingzhi Mushroom (*Ganoderma lucidum*) Extract Reduce the Number of Lymphocyte in Diabetics Rats with Periodontitis: In Vivo Experimental on *Sprague dawley* Rats

Pratitis Widi Seno¹^a, Amilia Ramadhani²^b, Saryono³^c, Haris Budi Widodo⁴^d
and Christiana C. Prihastuti⁴^e

¹*School of Dentistry, Medical Faculty of Jenderal Soedirman University, Purwokerto, Indonesia*

²*Departement of Biomedicine, School of Dentistry, Medical Faculty of Jenderal Soedirman University, Purwokerto, Indonesia*

³*Departement of Biochemistry, Nursing of Jenderal Soedirman University, Purwokerto, Indonesia*

⁴*Departement of Oral Biology, School of Dentistry, Medical Faculty of Jenderal Soedirman University, Purwokerto, Indonesia*

Keywords: Ganoderma lucidum, lymphocyte, periodontitis, diabetes mellitus.


Abstract: Periodontitis is a chronic inflammation on the periodontal tissue that is characterized by attachment loss and bone loss. Diabetes mellitus deteriorated the condition of periodontitis. Ganoderma lucidum has the potential as anti-inflammation and anti-oxidant agents that can hasten the convalescence of periodontitis disease. This research aims to understand the effect of oral administration of Ganoderma lucidum extract on the number of lymphocytes in Sprague dawley rats induced with diabetes mellitus and periodontitis. The results showed that the estimated number of lymphocytes in groups that given the extract decreased as the doses increased. The group with 20 mg/kgBW dose has the lowest lymphocyte count and approached the healthy control group. The results of the Kruskal-Wallis test showed that there are significant differences among the five treatment groups for the estimation of lymphocyte counts ($p < 0.05$). The Mann-Whitney test showed a significant difference between groups in estimating lymphocyte counts ($p < 0.05$). This research concludes that there is an effect of G. lucidum extract to the amount of lymphocyte in Sprague dawley rats designed with diabetes mellitus and periodontitis.


1 INTRODUCTION


Diabetes mellitus is a chronic disease that disrupts the body's metabolism so the body can't regulate blood glucose levels. Diabetes mellitus has several complications in the oral cavity, such as periodontitis, dry mouth, gingivitis, calculus, and alveolar bone resorption. Periodontitis occurs in patients with diabetes mellitus, with a prevalence of 75%. According to research conducted by Sari et al. (2017), 88.24% of people with diabetes in Sardjito Regional Hospital suffer from periodontitis.


Periodontitis is a chronic inflammatory disease caused by specific microorganism or groups of specific microorganisms. This infection was resulting in progressive destruction of the periodontal ligament and alveolar bone with increased probing depth formation, recession, or both (Newman et al, 2015). Lymphocytes, plasma cells and macrophages mediate the body's response during chronic inflammation (Stryer et al., 2012). Lymphocytes are specific immune defences to remove antigens, release antibodies, and provide cytokines for other immune cells (Kumar et al., 2015).

^a <https://orcid.org/0000-0002-9957-501X>

^b <https://orcid.org/0000-0001-8902-5164>

^c <https://orcid.org/0000-0002-3012-5328>

^d <https://orcid.org/0000-0003-2154-902X>

^e <https://orcid.org/0000-0002-0611-7651>

The hyperglycemia condition in diabetes mellitus can worsen the periodontal disease. High blood glucose level induces high secretion of pro-inflammatory cytokines and decreases the activity of chemotaxis, phagocytosis, and intracellular activity of lymphocyte. This alteration of the immune system stimulates delayed wound healing (Daniel et al., 2012; Mealey et al., 2006)

Diabetes mellitus and periodontitis have a two-way relationship. Diabetes mellitus produces Advanced Glycation End Products (AGEs), which can increase local expression of pro-inflammatory cytokines and enhanced the destruction of periodontal tissue (Preshaw et al. 2012). Otherwise, high levels of pro-inflammatory cytokines dysregulated blood glycemic levels and also increased risk of diabetic nephropathy, retinopathy, and heart disease. Diabetes mellitus and periodontitis conditions will increase the expression of IL-6. The high level of IL-6 will also increase the number of lymphocytes in the gingival tissue and worsen the periodontal inflammation (Wu et al., 2015).

Scaling, root planning, curettage of gingiva, and *Host Modulating Therapy* (HMT) were the golden standard of periodontitis therapy (Andriani 2012; Notoharjo & Sihombing 2015). Non-steroid anti-inflammation medicines such as ibuprofen and flurbiprofen can be used as host modulating therapies. In the contrary, the long-term use of anti-COX2 may lead to stomach ulcers and haemorrhage (Newman et al., 2015). The *Ganoderma lucidum* (*G. lucidum*) has a potent anti-inflammation effect and has a minimum long-term side effect (Li et al., 2011).

Ganoderma lucidum (Lingzhi mushroom or Reishi mushroom) contains triterpenoid, ganoderic acid, polysaccharide, protein, and unsaturated fat (Huang et al. 2018). These active substances have a potential effect of antioxidant, anti-inflammation, and anti-hyperglycemic (Ma et al. 2015; Ratnaningtyas et al., 2018; Huang et al., 2018). The previous study confirmed that ganoderic acid could inhibit the production of COX-2, and prevent the inflammation process (Ratnaningtyas et al., 2018).

Huang et al (2018) has proved that the provision of 10 mg/kg BB doses of *G. lucidum* extract in 7 days can decrease the amount of polymorphonuclear cells (PMN) and in 10 days, it can lead the bone forming. Polymorphonuclear cells are innate immune system of non specific body defense system while a specific immune system takes part in periodontitis (Berglundh & Donati 2005). One of the cells that takes part in the specific immune system is lymphocyte (Newman et al., 2015). The aim of this study was to examine the effect of oral administration of *G. lucidum* extract at

a dose of 5 mg/kg BW, 10 mg/kg BW, and 20 mg/kg BW for 7 days on the total number of lymphocytes in Sprague dawley rats induced with diabetes mellitus and periodontitis.

2 MATERIAL AND METHOD

This research was an experimental laboratory with posttest-only control group design. The study was conducted for 3 months, started from March to May 2019. This research used 30 rats with inclusion criteria of male Sprague dawley rats weighing about 200-300 grams, age of 2-3 months, and induced with periodontitis and diabetes mellitus with blood glucose levels >126 mg/dL. The rats were divided into 5 groups which include healthy control group (K1), negative control group (K2), 5 mg/kg BW dose group (P1), 10 mg/kg BW dose group (P2) and 20 mg/kg BW dose group (P3).

This study was approved by the Ethics Commission of Faculty of Medicine, Jenderal Soedirman University under Ref: 1394 / KEPK / III / 2019. The rats were adapted and placed in a room with sufficient air flow and light for one week. The extract was produced by dissolving 300 grams of *G. lucidum* mushroom simplicia using 96% ethanol in a ratio of 1: 5, then it was soaked for 3x24 hours. The mushroom extract filtrate was evaporated using a rotary evaporator until a thick extract was obtained. The extract was then dissolved with the dose of 5 mg / kg BW, 10 mg/kg B, and 20 mg / kgBB.

All the K2, P1, P2, P3 group samples were induced with diabetes mellitus by injecting streptozotocin (STZ) intraperitoneally at a dose of 40 mg / kg in 0.1 M citrate buffer pH 4.5 (Furman et al., 2015; Zulkarnain et al., 2013). Measurement of blood glucose was carried out on the third day after STZ induction (day 10). The diabetics rats were rats with glucose blood level >126 mg/dL (Su et al., 2006).

On day 11, K2, P1, P2, and P3 groups were induced with periodontitis by inoculating *P. gingivalis* bacteria into the labial maxillary incisors at a dose of 1 McFarland according to the standard bacterial test which is equivalent to a density of 10⁸ i.e. 200 microliters or 0.2 mL everyday within 4 days. On day 15, clinical examination showed that the rats' gingiva were reddish and suppurating. One rat of each groups were euthanized to examine the alveolar bone resorption radiographically (Figure 1). The oral administration of *G. lucidum* extracts and distilled water were given every 24 hours for 7 consecutive days using gastric tube. On day 25, the rats' blood samples were taken from the tail to measure post-

treatment blood sugar levels. The rats were euthanized using ether and the anterior maxillary gingival tissues were carefully extracted and stored in 10% formalin solution.

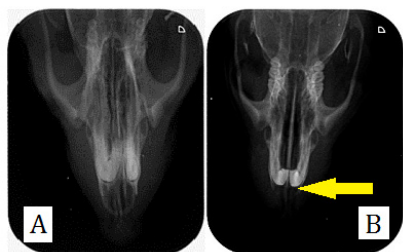


Figure 1: Radiograph image of rats alveolar bone (A) healthy rats ; (B) periodontitis rats; Yellow arrow showed bone resorption.

The dehydration, clearing, and embedding phases were performed in a tissue processor (Tissue Tex®, USA). The embedding process was carried out by the embedding center tool (Leica®, Germany). Pre-dehydration and post-clearing images of gingival tissue were documented for the calculation of the volume shrinkage. A grid composed of regularly spaced array of points made up using Image J® program was placed over the gingival tissue pre-dehydration and post-clearing images. The distance between points were 1.5 mm. The number of points falling on the images of gingival tissues were counted and used to calculate the volume shrinkage using the following formula (Nyengaard, 1999):

$$\text{Volume shrinkage} = \left(1 - \frac{\text{post-clearing area}}{\text{pre-dehydration area}}\right)^{1.5} \quad (1)$$

Paraffin blocks were sectioned at nominal thickness of 5µm using a Systematic Uniform Random Sampling (SURS) technique (Altunkaynak et al., 2012; Tschanz et al., 2014). A number between 1 and 20 was randomly chosen and this number pointed to the number of the section to be sampled together with its adjacent section. The following 18 sections were discarded and the subsequent pairs of section were sampled. This procedure was continued until the whole gingival tissue was exhaustively sectioned. The average number of pairs of section was 6 pairs. All sample sections were mounted on to glass slides and stained with Hematoxylin-eosin.

The gingival tissue volume was estimated using the Cavalieri principle. Images of the gingival tissue of one section from each pair of section of each rat were viewed under Olympus CX21FS1 (Olympus Singapore PTE, LTD) light microscope at 40X magnification and captured using Optilab CX-21

camera (PT Minocos, Indonesia). These images were combined in order to make a complete picture of gingival tissue using Adobe photoshop® CS6 software (Adobe System Incorporated, United States). The complete image was then viewed using ImageJ® software (NIH Image; National Institutes of Health, Bethesda, MD) and superimposed with regularly spaced array of test points at a distance of 3.4 mm between points. The areas represented by each point (a/p) were 11.56 mm². All points (P) which hit the gingival tissue were counted. The volume of gingival tissue was estimated using the following formula (Pulungan et al., 2018) :

$$\text{Volume} = T \cdot \frac{a}{p} \cdot \Sigma P \cdot (1 + \text{volume shrinkage}) \quad (2)$$

where “T” is the distance between sections (mm), “a/p” is the area per point (mm²), and ΣP is the total number of points.

The numerical densities of gingival tissue’s lymphocytes were determined using a physical dissector probe. The gingival tissue were viewed and captured at 400x magnification. The counting frame of 60 x 60 mm² was used for counting the profile of gingival tissue’s lymphocytes (Figure 2). The numerical density (Nv) of the lymphocytes was calculated using the following formula (Pulungan et al., 2018).

$$Nv = \frac{\Sigma Q^-}{\Sigma P \cdot a \cdot h \cdot (1 + \text{volume shrinkage})} \quad (3)$$

where “ΣQ-” is the sum of nucleoli profiles; “a” is the area of counting frames (µm²); “h” is the height of the dissectors which is equal to the section thickness (5 µm); and “ΣP” is the total number of counting frames. The total number of gingival tissue’s lymphocytes were estimated by multiplying the volume with the numerical density.

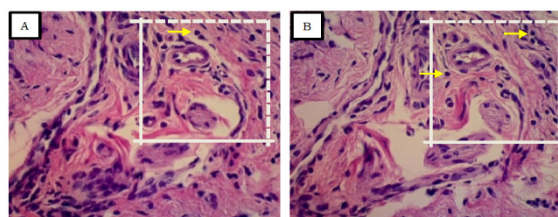


Figure 2 : Example of pairs of adjacent section; (A) Look up section; (B) Reference section. Dashed line of counting frame represent inclusion line, while full drawn line represent exclusion line. Yellow arrow showed counted lymphocyte.

The differences of total lymphocytes’ number of in all groups were analyzed using Kruskal-Wallis test

with confidence level of 95% ($p < 0,05$), since the data were not normally distributed. The Mann Whitney test were carry out with a confidence level of 95% ($p < 0,05$) to observe the differences of total lymphocytes' number between groups.

3 RESULT

The table 1 showed the rats' blood glucose level pre-treatment and post-treatment. The Levene test showed that the hyperglycemic state of each rat was different at the beginning of the study ($p < 0,05$).

Tabel 1: Blood glucose level (mg/dL) \pm SD

No.	Group	Pre treatment	Post treatment
1.	P1	214,2 \pm 43,2	240,2 \pm 52,9
2.	P2	220,8 \pm 73,0	188,0 \pm 50,9
3.	P3	439,4 \pm 97,6	352 \pm 76,9
4.	K1	79,8 \pm 24,0	-
5.	K2	363,2 \pm 151,76	312,75 \pm 107,2

P1: Groups of treatment with a dose of 5 mg/KgBB, P2: Groups of treatment with a dose of 10 mg/KgBB, P3: Groups of treatment with a dose of 20 mg/KgBB), K1: Healthy control, K2: Negative control

The total number of lymphocytes in each groups were shown in table 2. The total number of lymphocytes in the treatment group decreased as the doses of *G. lucidum* extract increased. Oral administration of 20 mg/KgBW *G. lucidum* extract decreased the total number lymphocytes related to healthy control.

Table 2: Total number of lymphocytes each groups

No.	Groups	Mean of estimated lymphocyte \pm SD	P
1.	P1	992,64 \pm 262,43	0,04
2.	P2	848,70 \pm 358,06	
3.	P3	322,85 \pm 226,73	
4.	K1	325,74 \pm 57,8	
5.	K2	1.006,49 \pm 488,08	

P1: Groups of treatment with a dose of 5 mg/kgBW, P2: Groups of treatment with a dose of 10 mg/kgBW, P3: Groups of treatment with a dose of 20 mg/kgBW), K1: Healthy control, K2: Negative control; p: Result of Kruskal-Wallis test

The Kruskal-Wallis test results showed that there were significant differences of the total number of lymphocytes between all groups ($p < 0,05$). Mann-Whitney Test results show that there is no significant

differences of total number of lymphocytes between the 5 mg / kgBW dose group (P1), 10 mg / kgBW dose group (P2), and the negative control group (K2). Otherwise, the total number of lymphocytes of the 20 mg / kgBB dose group (P3) was significant difference to the P1, P2, and K2 groups. This result showed that the total number of lymphocytes in group P3 similar to the healthy control group, since there were no significant difference with the healthy control group.

4 DISCUSSION

Inflammatory responses of periodontitis in conjunction with DM were different than periodontitis alone. DM condition accompanied by periodontitis reduces the function of neutrophils, monocytes, and macrophages in chemotaxis and phagocytosis (Mealey, 2006). According to Otton et al. (2002), the DM conditions affect lymphocyte metabolism. Glucose and glutamine metabolism of lymphocytes were altered so it requires more glucose but cannot oxidize their metabolites efficiently and caused decreased function of lymphocyte in immune system.

Hyperglycemic conditions caused some disruption in healing process such as a longer inflammatory phase. Mirza et al. (2014) stated that in the condition of diabetes mellitus, the inflammatory phase will reach the peak on the 5th day and start to decrease on the 10th day. Meanwhile, in the non-diabetes mellitus condition, the proliferation phase has begun on the 6th day. Changes in the period of inflammation will affect the healing process. In hyperglycemic conditions, reparative cells in the periodontium and fibroblast cannot work optimally so that the newly formed-collagen fibers were easily destroyed by MMP (Mealey, 2006). The DM condition modify the microvascular integrity, that is the formation of AGEs (Mirza et al., 2014). Inflammatory cells have AGEs receptor on the cell surface. When AGEs bound to inflammatory cells such as macrophages, monocytes, and lymphocytes, the production of proinflammatory cytokines will increase and resulted in the hyper-responsiveness of the immune system (Mealey, 2006).

The oral administration of 20 mg/kgBW *G. lucidum* extract showed a significant decrease of total number of lymphocytes compared to negative control group. Dudhgaonkar et al. (2009) argued that ganoderic acid and polysaccharides from *G. lucidum* extract decreased the proinflammatory cytokines such as TNF- α , IL-6, and PGE2 from LPS induced macrophages. As in vivo study showed that *G.*

lucidum extract act as anti-inflammatory and antiproliferative agents via inhibition of the NF- κ B and AP-1 signaling cycles in macrophages. Izzaty et al., (2014) study showed that hyperglycemic conditions cause a longer inflammatory phase, regarding to high number of lymphocytes observed on the 7th day of healing process. Our recent study showed that oral administration of *G. lucidum* extract for 7 consecutive days reduce the number of lymphocytes, so that the healing process accelerated.

Triterpenoids as antioxidants play a role to bind reactive ROS compounds such as superoxide anions (O₂⁻), so that the inflammatory response will decrease (Chen et al., 2016). The decrease in ROS will result in acceleration of proliferation phase by decreasing the production of IL-7, so the migration of leukocyte cells such as neutrophils and macrophages will decrease (Pushparani, 2015; Sari et al., 2017).

Polysaccharides optimize the macrophages, lymphocytes, and plasma cells to modulate the inflammatory process (Ratnaningtyas et al., 2018). Polysaccharide extract of *G. lucidum* has a hypoglycemic effect by reducing glucose levels in plasma in which it enhanced the activity and metabolism of lymphocytes. The treatment groups of the 5 mg/kgBW and 10 mg/kgBW *G. lucidum* extract statistically showed no significant difference with the negative control group. This shows that both doses have not reached the maximum effect in reducing the number of lymphocytes.

The oral administration of 20 mg/kg BW *G. lucidum* extract was the most optimum dose to reduce the number of lymphocytes in rats with periodontitis and diabetes mellitus condition. This result different from Huang et al. (2018) study that showed decreased number of neutrophils of periodontitis rats on day 7 after administration of 10 mg/kgBW *G. lucidum* extract. The persistent inflammatory response of neutrophils triggered lymphocytes to form a chronic inflammatory response. In this study, the hyperglycemic condition is responsible for the increase in the severity of periodontitis and the delayed of healing response.

The oral administration of 5 mg/kgBW, 10 mg/kgBW and 20mg/kgBW *G. lucidum* extract did not affect the hyperglycemic conditions of the rats. The post treatment glucose levels were decreased, but still remained in hyperglycemic conditions. Previous study confirmed antidiabetic effect of *G. lucidum* extract in higher dose. The administration of 50 mg/kg BW and 100 mg/kgBW *G. lucidum* extract prove to provide antidiabetic effects as measured by blood glucose levels and insulin levels of rats (Sirisidhi et al., 2016; Zhang & Lin, 2004).

This recent study showed that the oral administration of 20 mg/kgBW *G. lucidum* extract reduced the total number of gingival tissues' lymphocytes pronounced to the healthy control group. As the decreased number of lymphocytes indicate the reduced in periodontal inflammation process (Taubman & Kawai, 2001). The higher dose of *G. lucidum* extract will comprised the higher concentration of triterpenoids and polysaccharides and escalated the anti-inflammatory effect.

5 CONCLUSION

In conclusion, the *G. lucidum* extract intensify the inflammatory phase of healing process of periodontitis with diabetes mellitus. The total number of lymphocytes were decline resembling the healthy groups after oral administration of 20 mg/kg BW *G. lucidum* extract. Further study is required to examine the potential of *G. lucidum* extract to the next phases of healing process of periodontitis with diabetes mellitus.

REFERENCES

- Altunkaynak, B. Z., Önger, M. E., Altunkaynak, M. E., Ayranci, E., & Canan, S., 2012. A Brief Introduction To Stereology And Sampling Strategies: Basic Concepts Of Stereology. *Neuroquantology*, 10(1), Pp. 31–43.
- Andriani, I., 2012. Efektivitas Antara Scaling Root Planing (Srp) Dengan Dan Tanpa Pemberian Ciprofloxacin Per Oral Pada Penderita Periodontitis. *Insiva Dental Journal*, 1(2), Pp. 81–89.
- Berglundh, T., & Donati, M., 2005. Aspects Of Adaptive Host Response In Periodontitis. *Journal Of Clinical Periodontology*, 32(Suppl. 6), Pp. 87–107.
- Chen, T.-Q., Yang, C., Wu, J.-G., & Wu, J.-Z., 2016. Total Triterpenoids From The Ultrasonic-Circulating Extract Powder Of Ganoderma Lucidum And Its Antioxidant Activity In Vitro. *Ournal Of Chemical And Pharmaceutical Research*, 8(5), Pp. 730–735.
- Daniel, R., Gokulanathan, S., Shanmugasundaram, N., Lakshmigandhan, M., & Kavin, T., 2012. Diabetes And Periodontal Disease. *Journal Of Pharmacy And Bioallied Sciences*, 4(6), Pp. 280–283.
- Dudhgaonkar, S., Thyagarajan, A., & Sliva, D., 2009. Suppression Of The Inflammatory Response By Triterpenes Isolated From The Mushroom Ganoderma Lucidum. *International Immunopharmacology*, 9(11), Pp. 1272–1280.
- Furman, B. L., 2015. Streptozotocin-Induced Diabetic Models In Mice And Rats. *Current Protocols In Pharmacology*, 70(1), Pp. 5471-54720.

- Huang, P.-H., Hsieh, M.-C., Weng, P.-W., Cheng, W.-C., Chu, C.-L., Chen, D.-C., Sung, C.-E., & Huang, R.-Y., 2018. *Ganoderma Lucidum* Reduces Inflammation-Induced Bone Loss : A Pilot Study In Rats. 1(1), Pp. 35–40.
- Izzaty, A., Dewi, N., & Pratiwi, D. I. N., 2014. Ekstrakharuan (*Channa striata*) Secara Efektif Menurunkan Jumlah Limfosit Fase Inflamasi Dalam Penyembuhan Luka. *Journal Of Dentomaxillofacial Science*, 13(3), 176.
- Kumar, V., Abbas, A. K., & Aster, J. C., 2015. *Robbins And Cotran Pathologic Basic Of Disease* (Ninth Edit). Elsevier Ltd.
- Li, F., Zhang, Y., & Zhong, Z., 2011. Antihyperglycemic Effect Of *Ganoderma lucidum* Polysaccharides On Streptozotocin-induced Diabetic Mice. *International Journal Of Molecular Sciences*, 12(9), Pp. 6135–6145.
- Ma, H. T., Hsieh, J. F., & Chen, S. T., 2015. Anti-Diabetic Effects Of *Ganoderma lucidum*. *Phytochemistry*, 114, Pp. 109–113.
- Mealey, B. L., 2006. Periodontal Diseases And Diabetes: A Two-Way Street. *The Journal Of American Dental Association*, 137(12), Pp. 26s-31s.
- Mirza, R. E., Fang, M. M., Weinheimer-Haus, E. M., Ennis, W. J., & Koh, T. J., 2014. Sustained Inflammation Activity In Macrophages Impairs Wound Healing In Type 2 Diabetic Humans And Mice. *Diabetes*, 63(3), Pp. 1103–1114.
- Newman, M. G., Takei, H. H., & Klokkevold, P. R., 2015. *Carranza's Clinical Periodontology* (F. A. Carranza (Ed.); 12th Ed.). Elsevier.
- Notoharjo, I. T., & Sihombing, M., 2015. Faktor Resiko Pada Penyakit Jaringan Periodontal Gigi Di Indonesia (Riskasdas 2013). *Buletin Penelitian Sistem Kesehatan*, 18(1), Pp. 87–94.
- Nyengaard, J.R., 1999. Stereologic Methods And Their Application In Kidney Research. *Journal Of The American Society Of Nephrology : Jasn*, 10(5), Pp. 1100–1123.
- Oton, R., Mendonça, J. R., & Curi, R., 2002. Diabetes Causes Marked Changes In Lymphocyte Metabolism. *Journal Of Endocrinology*, 174(1), Pp. 55–61.
- Preshaw, P., Alba, A., Herrera, D., Jepsen, S., Konstantinidis, A., Makrilakis, K., & Taylor, R., 2012. Periodontitis And Diabetes: A Two-Way Relationship. *International Journal Of Evidence-Based Healthcare*, 55, Pp. 21–31.
- Pulungan, Z. S. A., Sofro, Z. M., & Partadiredja, G., 2018. Sodium Fluoride Does Not Affect The Working Memory And Number Of Pyramidal Cells In Rat Medial Prefrontal Cortex. *Anatomical Science International*, 93(1), Pp. 128–138.
- Pushparani, D., 2015. Role Of Cytokines In Periodontal Wound Healing Process - A Review. *Pharmaceutical Analytical Chemistry: Open Access*, 01(01), Pp. 1–5.
- Ratnaningtyas, N. I., Hernayanti, H., Andarwanti, S., Ekowati, N., Purwanti, E. S., & Sukmawati, D., 2018. Effects Of *Ganoderma lucidum* Extract On Diabetic Rats. *Biosaintifika: Journal Of Biology & Biology Education*, 10(3), Pp. 642–647.
- Sari, R., Herawati, D., Nurcahyanti, R., & Wardani, P. K., 2017. Prevalensi Periodontitis Pada Pasien Diabetes Mellitus (Studi Observasional Di Poliklinik Penyakit Dalam Rsup Dr. Sardjito). *Majalah Kedokteran Gigi Indonesia*, 3(2), Pp. 98.
- Sirisidithi, K., Kosai, P., & Jiraungkoorskul, W., 2016. Antidiabetic Activity Of The Lingzhi Or Reishi Medicinal Mushroom *Ganoderma lucidum*: A Review. *Sa Pharmaceutical Journal*, 83(8), 45–47.
- Stryer, D. S., Rubin, E., Saffitz, J. E., & Schiller, A. L., 2012. *Rubin's Pathology*. Wolters Kluwer Health.
- Su, H. C., Hung, L. M., & Chen, J. K., 2006. Resveratrol, A Red Wine Antioxidant, Possesses An Insulin-Like Effect In Streptozotocin-Induced Diabetic Rats. *American Journal Of Physiology - Endocrinology And Metabolism*, 290(6), Pp. 1339–1346.
- Taubman, M. A., & Kawai, T., 2001. Involvement Of T-Lymphocytes In Periodontal Disease And In Direct And Indirect Induction Of Bone Resorption. *Critical Reviews In Oral Biology And Medicine*, 12(2), Pp. 125–135.
- Tschanz, S., Schneider, J. P., & Knudsen, L. (2014). Design-Based Stereology: Planning, Volumetry And Sampling Are Crucial Steps For A Successful Study. *Annals Of Anatomy*, 196(1), Pp. 3–11. <https://doi.org/10.1016/j.aanat.2013.04.011>
- Wu, Y. Y., Xiao, E., & Graves, D. T. (2015). Diabetes Mellitus Related Bone Metabolism And Periodontal Disease. *International Journal Of Oral Science*, 7(2), Pp. 63–72.
- Zhang, H. N., & Lin, Z. Bin., 2004. Hypoglycemic Effect Of *Ganoderma lucidum* Polysaccharides. *Acta Pharmacologica Sinica*, 25(2), Pp. 191–195.
- Zulkarnain., 2013. Perubahan Kadar Glukosa Darah Puasa Pada Tikus Sprague Dawley Yang Diinduksi Streptozotocin Dosis Rendah. *Jurnal Kedokteran Siah Kuala*, 13(2), Pp. 71–76.