

# Hard Tissue Surgical Treatment with Embedded Dental Condition of Tuberosity Maxillary

Bambang Tri Hartomo<sup>1</sup><sup>a</sup>, and Rizka Rachmatika Dewi<sup>2</sup><sup>b</sup>

<sup>1</sup>Dental Medicine Study Program, Faculty of Medicine, Jenderal Soedirman University, Purwokerto, Indonesia

<sup>2</sup>Student of Dental Medicine Study Program, Faculty of Medicine, Jenderal Soedirman University, Purwokerto, Indonesia

**Keywords:** Hard tissue surgical, embedded, tuberosity maxillary.

**Abstract:** An embedded tooth is a tooth condition that cannot erupt due to obstruction by bone. The state of a hidden tooth located near the nerve will cause pain due to persistent pressure on the nerve. The extraction of the hidden tooth is performed by surgery, namely odontectomy. This case report aimed to know the hard tissue surgical treatment performed in an embedded tooth in maxillary tuberosity. The case report is about a 23 years old woman with frequent headaches since five years ago and pain in the left temple area and the left maxillary region. The results of the palpation examination on the left temporal site are tender. The supporting examination results in panoramic radiological radiographs were obtained from tooth 27, which had a horizontal class IIIC impacted with the crown distally. The removal of the embedded tooth was performed by odontectomy procedure and administration of medication antibiotics and analgesics.

## 1 INTRODUCTION


The Indonesian citizen's level of awareness regarding oral and dental health is still deficient, so it is often found that patients come for treatment when they are already experiencing unbearable pain. Patients who come for treatment when they already experience unbearable pain dramatically affect the treatment plan carried out by the dentist. Conditions for tooth decay, such as teeth with extensive caries and leaving minimal tooth structure, require several treatment types to get maximum results (Taufiqurrachman and Mulyo, 2016).


Hard tissue surgery is a branch of oral surgery in dentistry that studies things related to hard tissue surgery in the oral cavity. Some of the oral surgery treatments are tooth extraction, and odontectomy in an impacted an embedded tooth. The bone reduction to assist in the extraction of teeth with difficult conditions and alveolectomy in exostotic conditions. Tooth extraction can be performed using two methods: the intra alveolar extraction technique and the trans alveolar extraction technique or surgery. The trans alveolar extraction technique is used to extract a tooth with difficult conditions, such as teeth with root

deformities, namely dilation and fusion, hypersementosis, ankylosis, and the tooth that enter the maxillary sinus. Extraction of a tooth with difficult conditions is an extraction that requires opening the soft tissue flap, removing bone or cutting the tooth (Lande et al., 2015).

Hard tissue surgery is a surgical procedure in the field of oral surgery to eliminate the infection in the tooth and hard tissue in the patient's oral cavity. Several kinds of conditions in the tooth and oral cavity that require hard tissue surgery include the state of the impacted tooth, buried root tooth and exostosis. Impaction is a tooth condition that cannot erupt in the jaw arch at the time of eruption (Arisetiadi et al., 2017).

The embedded tooth is tooth conditions that cannot erupt due to obstruction by bone. Extraction is performed when embedded tooth causes various symptoms that can interfere with the patient's activities, such as disrupting the chewing function and causing complications. Complications include pathological resorption of the adjacent tooth, the formation of follicular cysts, pericoronitis and neuralgic pain (Saleh et al., 2015). The condition of the embedded tooth located near the nerve will cause pain due to persistent pressure on the nerve (Hupp et

<sup>a</sup> <https://orcid.org/0000-0002-9791-1200>

<sup>b</sup> <https://orcid.org/0000-0003-4583-2145>

al., 2019). Embedded conditions can cause complaints such as pain so that the patient feels uncomfortable and disturbed. The pain results from persistent pressure on the nerves around the embedded tooth. Pain that occurs as a result of dental problems is included in myofascial pain. Myofascial pain is a condition of muscle pain or facial pain, acute and chronic and interferes with sensory and motor functions (Bahrudin, 2017). The tooth that is often impacted or embedded in the posterior tooth, including mandibular third molars, maxillary third molars, mandibular premolars, and maxillary premolars. Anterior tooth such as canines and incisors can also be impacted on either the maxilla or the mandible. The maxillary second molar's Impaction is relatively rare, with a prevalence rate of 0.08% (Zakaria, 2015).

The angulation positions of the impacted teeth of the maxillary and mandibular third molars had the opposite degree of difficulty. The most difficult to remove for the maxillary third molar was mesioangular angulation (directly opposite to the impacted mandibular third molar) versus vertical or distoangular angulation. The mesioangular impact is the most challenging difficulty to remove because the bone lining or covering the impacted tooth requires removal or expansion in the tooth's posterior aspect. Access to the teeth in the mesioangular position is complicated to reach if the maxillary second molar's eruption is in place. The angulation of impacted teeth of the maxillary and mandibular third molars have the opposite degree of difficulty. The most difficult to remove for the maxillary third molar was mesioangular angulation (directly opposite to the impacted mandibular third molar) versus vertical or distoangular angulation. The mesioangular impact is the most challenging difficulty to remove because the bone lining or covering the impacted tooth requires removal or expansion in the tooth's posterior aspect. Access to the teeth in the mesioangular position is complicated to reach if the maxillary second molar's eruption is in place (Tammama, 2018).

The extraction of the embedded tooth is performed by surgery. Extraction with a surgical technique is called odontectomy (Fitri et al., 2016). Odontectomy is a treatment performed to remove a tooth that can erupt, partially erupt and non-erupted tooth (Fakhrurrazi et al., 2015). Odontectomy is a surgical extraction procedure that requires creating a mucoperiosteal flap and removing the bone blocking the tooth. This action requires good preparation and accuracy in planning. It is done not to cause unwanted complications, such as oedema, trismus and paresthesia (Roi et al., 2019). The aim of this case

report is knowing the hard tissue surgical treatment performed in the condition of embedded tooth in maxillary tuberosity.

## 2 CASE

A 23 years old female patient came with complaints of frequent headaches since five years ago. Patients often feel pain in the left temple area as well as the left maxilla area. The patient has a habit of chewing using both sides of the jaw. The extraoral examination results, when the palpation examination was carried out in the left temporal area, there was mild tenderness. A temporomandibular joint investigation found no abnormalities and pain. The intraoral study results were no teeth 18, 17, 27, 28, and 38. Examination of palpation in the left maxillary tuberosity felt a slight bulge in the distal part. Analysis of the vestibule of tooth 27 showed mild tenderness. It was found that both maxillary second molars had horizontal class IIIC impactions with the crown distally and there were no images of the right and left third molars in the upper jaw and the lower left third molar.

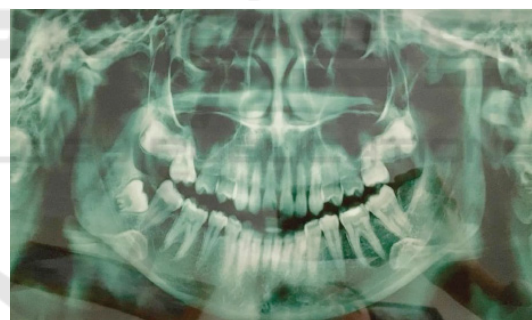

Figure 1. Panoramic radiograph

The diagnosis in the case was embedded tooth 37. The treatment plan, in this case, was odontectomy.

The odontectomy procedure begins with performing asepsis of the work area using povidone-iodine. The buccal anaesthesia in the space of tooth was performed. An anaesthetize posterior superior alveolar nerve and tooth 27 to anaesthetize palatinus major nerve was conducted in the palatal region. Anaesthesia checks are carried out using an excavator or tweezers by comparing the area under anaesthesia with the area that was not anaesthetized. The next step was to make an incision to create the mucoperiosteum flap and the left maxillary second molar. The flap is opened using a raspatorium, and then the alveolar process is taken from the buccal part that covers the tooth with a bone bur. The visible tooth was removed

using beins and extraction forceps. The socket where it was removed is debrided by taking the granulation tissue and smoothing the sharp bone. The next step is to perform irrigation using sterile saline and continues with suturing. The patient is instructed to bite the tampon. The patient was given postoperative instructions and medication in the form of antibiotics and analgesics.

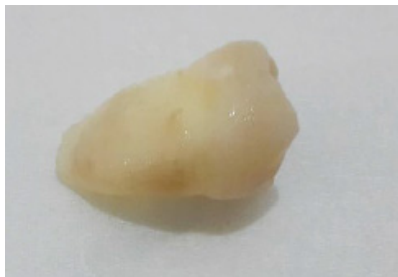

Figure 2. The left maxillary second molar after omentectomy

### 3 DISCUSSION

A hard tissue surgery is a branch of oral surgery that studies things related to hard tissue surgery in the oral cavity, such as odontectomy in the case of impacted and embedded tooth, bone reduction to help the extraction process of the tooth with challenging conditions and alveolectomy in cases exostosis or bony prominence (Haggerty and Laughlin, 2015). The state of an impacted tooth is a condition of the tooth which partially or cannot fully erupt due to obstruction or obstruction by an adjacent tooth or pathological tissue (Lande et al., 2015).



The embedded tooth is a tooth condition that cannot wholly erupt due to obstruction by bone. The implanted root is a condition where the remaining root of the tooth is not treated when the tooth is necrotic so that over time the alveolar and gingiva will cover the remaining root of the tooth. The embedded tooth usually occur in mandibular third molars and maxillary third molars (Saleh et al., 2015). The tooth cannot erupt because of the tooth's small arch or horizontal position (Roi et al., 2019). The tooth that is often impacted or embedded in the posterior tooth, including mandibular third molars, maxillary third molars, mandibular premolars and maxillary premolars. Anterior tooth such as canines and incisors can also impact either the maxilla or the mandible (Zakaria, 2015).

Winter's classification divides the conditions of impacted mandibular third molars based on the long axis of the tooth or the position of the impacted

mandibular third molar against the mandibular second molar, among others:

Table 1. Winter Classification

Class	Description	Figure
Class 1	It is called a mesioangular impacted tooth, or it is oblique to the mesial direction because the third molar is tilting the second molar in a mesial direction.	<p>Figure 2. Class 1</p> <p>Source: Hupp et al. (2019)</p>
Class 2	It is called a distoangular or tilted distally impacted tooth because the condition of the third molar's long axis is directed distally or posteriorly so that it is away from the second molar.	<p>Figure 3. Class 2</p> <p>Source: Hupp et al. (2019)</p>
Class 3	It is called a vertical impacted tooth because of the third molar points' long axis in the same direction as the second molar axis.	<p>Figure 4. Class 3</p> <p>Source: Hupp et al. (2019)</p>
Class 4	It is called a horizontally impacted tooth because the third molar's long axis is flat or horizontal to the second molar's long axis.	<p>Figure 5. Class 4</p> <p>Source: Hupp et al. (2019)</p>
Class 5	It is called a buccoangular impacted tooth because the long axis of the third molar is directed buccal to the second molar's long axis.	<p>Figure 6. Class 5</p>

		Source: Hupp et al. (2019)
Class 6	It is called a linguoangular impacted tooth because the long axis of the third molar points lingually towards the second molar's long axis.	 <p>Figure 7. Class 6</p> <p>Source: Hupp et al. (2019)</p>
Class 7	It is called an inverted impacted tooth because the third molar is embedded with the third molar's long axis pointing apically.	 <p>Figure 8. Class 7</p> <p>Source: Hupp et al. (2019)</p>

(Hupp et al., 2019)

Pell and Gregory's classification divided the impacted conditions of the third molars based on two factors: the relationship of the ramus to the space available and the relative depth of the third molars. The relationship between the ramus and the available space is divided into three classes, including class I, class II, and class III. Class I is the space available between the mandibular ramus and the mandibular second molar's distal surface, sufficient for the mesiodistal size of the mandibular third molar crown. Class II, the space available between the mandibular ramus and the mandibular second molar's distal surface is smaller than the mesiodistal size of the mandibular third molar crown. Class III, namely that there is no space available between the ramus of the mandibular and the distal surface of the mandibular second molar so that the tooth is mostly or entirely located in the ramus. Based on the third molar's relative depth, it is divided into three positions, namely position A, position B, and position C. Position A is that the occlusal plane of the third molar is at the same level as the occlusal plane of the second molar. Position B is the third molar's occlusal plane between the occlusal plane and the cervical line of the second molar. Position C, which is the third molar's occlusal plane, is below the cervical line of the second molar (Lita and Hadikrishna, 2020).

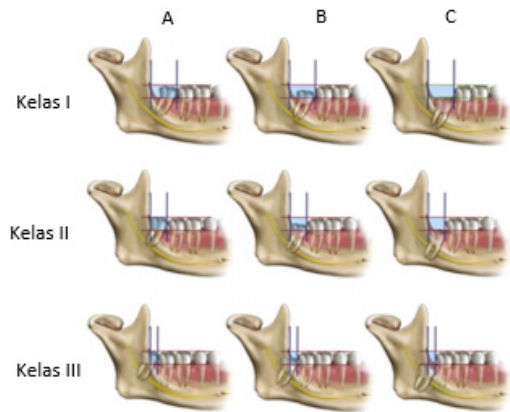


Figure 9. Pell and Gregory classification  
Source: Lita and Hadikrishna (2020)

The embedded tooth condition occurs because the crown cannot erupt either partially or entirely. After all, it is blocked by bone. According to Winter, the implanted tooth in the classification is included in class 7, whereas according to Pell and Gregory, the embedded tooth are in class IIC and class IIIC (Hupp et al., 2019).

Embedded conditions can cause complaints such as pain so that the patient feels uncomfortable and disturbed. The pain results from persistent pressure on the nerves around the embedded tooth. Pain that occurs as a result of dental problems is included in myofascial pain. Myofascial pain is a condition of muscle pain or facial pain, acute and chronic and interferes with sensory and motor functions. Pain occurs due to tissue damage that secretes histamine and bradykinin so that C fibres will increase the response to the peripheral areas by serotonin, prostaglandins, thromboxane and leukotrienes (Bahrudin, 2017). Substance P is released in the periphery, and increase peripheral vasodilation, sensitisation C fibres. C fibres will deliver impulses to the spinal cord's dorsal horn (Atmadja, 2016).

The procedure for the embedded tooth is odontectomy. This treatment aims to prevent the occurrence of a pathological condition originating from the follicle and infection caused by the inability to erupt or not fully erupt so that it can cause various kinds of pain complaints (Domingos et al., 2019). Odontectomy is a tooth extraction procedure for a tooth that cannot erupt, partially erupt or a tooth that cannot be extracted (Fakhrurrazi et al., 2015).

The odontectomy procedure begins with investigations, flap creation, bone reduction and tooth extraction. Studies are needed before an odontectomy is performed. The supporting examination function is to find out the anatomy around the tooth to be

performed, the condition around the bones, the shape of the roots, the number of roots, the length of the roots, and whether there is hypercementosis or not. The supporting examination used before an odontectomy is taking extra-oral X-rays using a panoramic technique (Saptadi et al., 2019). Odontectomy for embedded tooth requires precision and precision when extracting tooth using beins and extraction forceps. Anatomical structures such as blood vessels and sinuses and nerves around the tooth also need to be considered in the odontectomy of the embedded tooth. The management of odontectomy in the implanted tooth's condition begins with the asepsis procedure followed by anaesthesia (Sahetapy et al., 2015).

The stage after the supporting examination is making a flap. A flap is a surgical procedure that separates the mucosa from the underlying tissue. The flap aims to obtain visibility and accessibility to the alveolar bone. The flap in surgery has several conditions, including forms with a surgical incision, must have an adequate blood supply, sufficient flap size, have good visualization, flap design does not damage the anatomical structure, can return the tissue to its original or initial position and can be sutured with a sound healing process. There are various classifications of flaps, namely based on thickness and based on an outline. Based on the thickness, there are two types of flap: full-thickness flap or mucoperiosteal flap and partial thickness flap of the mucosal flap. A full-thickness flap is a flap used to gain access to the bone surface by separating the bone's soft tissue. This flap consists of the gingiva, mucosa, submucosa and alveolar periosteum (Yolcu and Acar, 2015).

The next step was to make an incision to create the mucoperiosteum flap, and the flap was opened using a raspatorium, and then the alveolar process was taken that covered the teeth using a bone bur. The visible tooth is cut into two parts to make it easier to retrieve. A tooth that has been cut is removed using a bein and extraction forceps. The socket where it was removed was debrided in taking granulation tissue and smoothing the sharp bone and then doing irrigation using sterile saline. The next step was suturing the socket, and the patient was instructed to bite the tampon. The patient was given postoperative instructions and medication in antibiotics and analgesics (Sahetapy et al., 2015).

Medication after hard tissue surgery is needed to prevent post-surgical complications. Medicines used after hard tissue surgery are antibiotics, analgesics and anti-inflammatory. Antibiotics, analgesics and anti-inflammatory agents in postoperative and simple

tooth extraction procedures are slightly different. The difference in medication is in choosing the type of medicine, which is the size or not the wound healing after the action. Antibiotic medication can be given as a prophylaxis to prevent infection in patients with a high risk of disease. It can be given post-surgery to prevent infection after the procedure (Lukito, 2019).

Analgesic medication is given after surgery to relieve pain or relieve pain. A few hours after the surgery, the numbness or numbness from anaesthesia will slowly return to normal, causing pain. The pain that appears can be reduced if given analgesic medication. Analgesics are divided into two groups, namely non-opioid anaesthetics and opioid analgesics. Non-opioid painkillers, also called NSAID analgesics, are the anaesthetics most often used in dentistry. NSAID anaesthetics inhibit cyclooxygenase, where cyclooxygenase synthesizes prostaglandins, thromboxane and prostacyclin which are pain mediators. Based on the way NSAID analgesics work, it can be used as a drug to treat pain due to inflammation after extraction and surgery (Taufiqurrachman and Mulyo, 2016).

#### 4 CONCLUSIONS

The tooth condition that has been impacted, embedded, exostotic, and the state of the tooth with complications, namely having variations in the roots' anatomical shape, such as bent or macerated roots, mostly cause complaints and pain. Pain and complaints can be relieved by taking care or treatment for these conditions. The treatment that can be given is by performing hard tissue surgery.

Hard tissue surgery that can be done is extraction with surgical techniques, namely odontectomy. The odontectomy procedure aims to remove the infection source so that complaints of pain and discomfort will disappear. Providing medication in the form of prophylactic medication and post-surgery significantly affects infection prevention, wound healing process, and overcoming patients' pain after surgery.

#### REFERENCES

- Arisetiadi, K. N. ., Hutomo, L. ., & Septarini, N. . (2017). Hubungan Antara Gigi Impaksi Molar Ketiga dengan Kejadian Karies Molar Kedua Berdasarkan Jenis Kelamin dan Usia pada Mahasiswa Fakultas Kedokteran Universitas Udayana. *Bali Dental Journal*, 1(1), 29–38.

- Atmadja, A. S. (2016). Sindrom Nyeri Myofasial. *Cermin Dunia Kedokteran*, 43(3), 176–179. <http://www.cdkjournal.com/index.php/CDK/article/download/29/26>
- Bahrudin, M. (2017). Patofisiologi Nyeri (Pain). *Saintika Medika*, 13(1), 7–13. <https://doi.org/10.22219/sm.v13i1.5449>
- Domingos, J., Suwarman, & Kestriani, N. D. (2019). Pengaruh Deksmetason 0,2 mg/KgBB sebagai Adjuvan Analgesia terhadap Waktu Kejadian Nyeri Pascaoperasi Odontektomi dengan Nrs>3. *Jurnal Anestesi Perioperatif*, 7(3), 168–174.
- Fakhrurrazi, Hakim, R. F., & Rifani, R. (2015). Hubungan Tingkat Kesulitan dengan Komplikasi Post Odontektomi Gigi Impaksi Molar Ketiga Rahang Bawah pada Pasien di Instalasi Gigi dan Mulut RSUDZA Banda Aceh. *Cakradonya Dent J*, 7(1), 761–767. <https://doi.org/10.1017/CBO9781107415324.004>
- Fitri, A. M., Kasim, A., & Yuza, A. T. (2016). Impaksi gigi molar tiga rahang bawah dan sefalgia. *J Ked Gi Unpad*, 28(3), 148–154. <https://doi.org/10.24198/jkg.v28i3.18691>
- Haggerty, C. J., & Laughlin, R. M. (2015). *Atlas of Operative Oral and Maxillofacial Surgery*. WILEY Blackwell. <https://doi.org/10.1002/9781118993729.ch2>
- Hupp, J. R., Ellis, E., & Tucker, M. R. (2019). *Contemporary Oral and Maxillofacial Surgery* (7th ed.). Elsevier. <https://doi.org/10.1017/CBO9781107415324.004>
- Lande, R., Kepel, B. J., & Siagian, K. V. (2015). Gambaran Faktor Risiko Dan Komplikasi Pencabutan Gigi Di Rsgm Pspdg-Fk Unsrat. *Jurnal E-GIGI*, 3(2), 476–481. <https://doi.org/10.35790/eg.3.2.2015.10012>
- Lita, Y. A., & Hadikrishna, I. (2020). Klasifikasi Impaksi Gigi Molar Ketiga Melalui Pemeriksaan Radiografi sebagai Penunjang Odontektomi. *Jurnal Radiologi Dentomaksilofasial Indonesia*, 4(1), 1–5. <https://doi.org/10.32793/jrdi.v4i1.467>
- Lukito, J. I. (2019). Antibiotik Profilaksis pada Tindakan Bedah. *Cermin Dunia Kedokteran*, 46(12), 777–783.
- Roi, C. I., Ianes, E., Gaje, P. N., Nica, D. F., Roi, A., & Roi, A. (2019). The predictability of Difficulty of Lower Third Molar Odontectomy. *REV.CHIM*, 70(4), 1342–1345. <https://doi.org/10.37358/rc.19.4.7123>
- Sahetapy, D. T., Anindita, P. S., & Hutagalung, B. S. P. (2015). Prevalensi Gigi Impaksi Molar Tiga Partial Erupted Pada Masyarakat Desa Totabuan. *Jurnal E-GIGI*, 3(2), 641–646. <https://doi.org/10.35790/eg.3.2.2015.10810>
- Saleh, E., Prihartiningsih, & Rahardjo. (2015). Odontektomi Gigi Molar Ketiga Mandibula Impaksi Ektopik dengan Kista Dentigerous secara Ekstraoral. *Majalah Kedokteran Gigi Klinik*, 1(2), 85–91. <https://doi.org/10.22146/mkgk.11956>
- Saptadi, A., Lilies, D. S., Menik, P., & Latief, B. S. (2019). Evaluation of Impacted Mandibular Third Molar Position in Relation to Mandibular Canal on Panoramic Radiography compared to Cone-Beam Computed Tomography. *Journal of International Dental and Medical Research*, 12(2), 591–596.
- Tammama, T. (2018). Impaksi Horizontal Gigi Molar Kedua Maksila Bilateral Simptomatis yang Menyebabkan Nyeri Kepala Rekuren Horizontal impaction of symptomatic bilateral maxillary second molar causing recurrent headache. *J Ked Gi Unpad*, 30(3), 158–161. <https://doi.org/10.24198/jkg.v30i3.18082>
- Taufiqurrachman, T., & Mulyo, K. (2016). Perbandingan Pengaruh Pemberian Analgetik Etoricoxib Dengan Natrium Diclofenak Terhadap Rasa Nyeri Pasca Odontektomi (Impaksi Kelas 1, Molar 3 Rahang Bawah). *Jurnal Kedokteran Diponegoro*, 5(3), 222–234.
- Yolcu, U., & Acar, A. H. (2015). Comparison of a New Flap Design with The Routinely used Triangular Flap Design in Third Molar Surgery. *International Journal of Oral and Maxillofacial Surgery*, 1–8. <https://doi.org/10.1016/j.ijom.2015.07.007>
- Zakaria, K. (2015). Sistem Pakar Diagnosa Penyakit THT Menggunakan Metode Dempster Shafer. *Prosiding Seminar Informatika Aplikatif Polinema*, 175–178. <https://doi.org/10.22219/repositor.v2i9.776>